

Demonstration of the Rationale for Therapeutic Drug Monitoring of Isavuconazole: A Case Report with a Lung Transplant Recipient

Eliška Dvořáčková¹, Andrea Zajacová², Jan Havlín³, Eva Klapková⁴, Robert Lischke³, Ondřej Slanař¹, Martin Šíma¹

¹Institute of Pharmacology, First Faculty of Medicine, Charles University and General University Hospital in Prague, Prague, Czech Republic;

²Prague Lung Transplant Program, Department of Pneumology, Second Faculty of Medicine, Charles University and University Hospital Motol, Prague, Czech Republic;

³Prague Lung Transplant Program, 3rd Department of Surgery, First Faculty of Medicine, Charles University and University Hospital Motol, Prague, Czech Republic;

⁴Department of Medical Chemistry and Clinical Biochemistry, Second Faculty of Medicine, Charles University and University Hospital Motol, Prague, Czech Republic

Received August 23, 2023; Accepted November 15, 2023.

Key words: Isavuconazole – Antifungals – Pharmacokinetics – Therapeutic drug monitoring – Lung transplant recipient

Abstract: Mucormycosis is a rare invasive fungal disease diagnosed in immunocompromised patients, including those with diabetes or iron overload, and in patients treated for hematological malignancies or after transplantation. Isavuconazole is a triazole antifungal effective against Mucorales with good tolerability, but with potential for relatively high interindividual variability in pharmacokinetics. This report demonstrates the case of a lung transplant recipient treated with isavuconazole that exhibits a very long elimination half-life of 159 hours, and discusses the practical implications of this finding for dosage adjustment and need for therapeutic drug monitoring.

This study was supported by the MH CZ-DRO (University Hospital Motol, Prague, Czech Republic, 00064203), and by the Charles University project Cooperatio (research area PHAR).

Mailing Address: Assoc. Prof. PharmDr. Martin Šíma, PhD., Institute of Pharmacology, First Faculty of Medicine, Charles University and General University Hospital in Prague, Albertov 4, 128 00 Prague 2, Czech Republic; Phone: +420 224 968 161; e-mail: martin.sima@lf1.cuni.cz

Introduction

Lung transplant recipients are at significant risk of invasive mycotic infection (Pappas et al., 2010). Isavuconazole, a new broad-spectrum triazole antifungal, is the most recently approved agent for the treatment of systemic fungal infections (aspergillosis and mucormycosis) with the good tolerability of long-term isavuconazole prophylaxis and treatment in lung transplant recipients (Marty et al., 2016; Monforte et al., 2022).

Isavuconazole can be administered parenterally (as an intravenous infusion) or orally (as hard capsules). Following oral administration, isavuconazole exhibits very high absolute bioavailability of 98%, allowing interchangeable use of intravenous and oral dosing. Isavuconazole is highly bound to plasma proteins (> 99%) and its steady-state volume of distribution (Vd) of 450 L indicates extensive distribution. Majority of drug is metabolized via CYP3A enzymes and subsequently via glucuronosyltransferases. Metabolites are excreted both through the urine and faeces. Only less than 1% of the dose administered is excreted renally in unchanged form (EMA, 2015).

The recommended posology consists of loading dose of 200 mg every 8 hours for the first 48 hours followed by maintenance dose of 200 mg once daily (EMA, 2015). There is still no clear consensus on the need for routine therapeutic drug monitoring (TDM) of isavuconazole in clinical practice. While some authors found no exposure-response relationship and thus concluded that there was no evidence for TDM (Desai et al., 2017), another study identified steady-state trough level of 5 mg/l as a threshold for toxicity (Furfaro et al., 2019) and the European Committee on Antimicrobial Susceptibility Testing (EUCAST) has set the clinical breakpoint at 2 mg/l for *Aspergillus fumigatus* and *Aspergillus flavus* (EUCAST, 2020).

The aim of this report is to demonstrate the case of a lung transplant recipient treated with isavuconazole that exhibits a very long elimination half-life, and to discuss the practical implications of this finding for dosage adjustment and need for TDM.

Case report

This case report was approved by the local Ethics Committee under the No. EK-873/22. Written informed consent was obtained from patient before data collection and analysis. A 70-year-old female (height 160 cm, weight 50 kg) received a bilateral lung transplantation in May 2022 for chronic obstructive pulmonary disease. During the transplantation, the right upper lobe was resected due to the oversized graft. Antithymocyte globulin and perioperative plasmapheresis were used as induction, followed by maintenance immunosuppression regimen consisting of tacrolimus, mycophenolic acid and prednisolone. Voriconazole, azithromycin, trimethoprim-sulfamethoxazole and valganciclovir were used as a prophylactic anti-infective treatment. The patient was dismissed 5 weeks after transplantation in mid-June in a good clinical condition, with physiological values of pulmonary function tests.

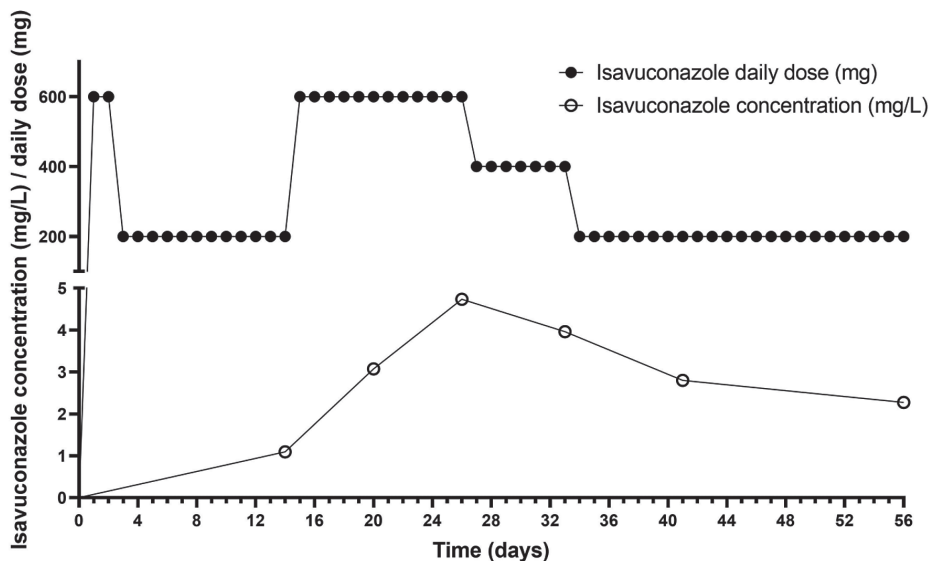


Figure 1 – Isavuconazole daily doses and plasma concentrations in the course of therapy.

In August, the patient was readmitted with severe type 1 respiratory failure with leukocytosis and elevation of C-reactive protein. Serum creatinine, alanine aminotransferase, aspartate aminotransferase and gamma-glutamyltransferase at admission were 130 $\mu\text{mol/l}$, 0.37 $\mu\text{kat/l}$, 0.22 $\mu\text{kat/l}$ and 2.82 $\mu\text{kat/l}$, respectively. Thoracic CT (computed tomography) showed a newly formed decay cavity in the lower lobe of the right lung, suspicious of mycotic infection. Bronchoscopy with BAL (bronchoalveolar lavage) sampling was performed – microscopy, cultivation and PCR were positive for *Rhizopus microsporus*. Antifungal therapy with both intravenous (Ambisome[®]) and inhalation (Fungizone[®]) amphotericin B and intravenous isavuconazole (Cresemba[®]) was started. The duration of inhalation amphotericin B, intravenous amphotericin B and intravenous isavuconazole therapy was 31, 48 and 55 days, respectively. Subsequently, the patient continues with oral isavuconazole therapy until present day. The course of dosing and measured isavuconazole levels during intravenous therapy is shown in Figure 1. *Mucor* infection was regularly monitored by bronchoscopy at 1–3 monthly intervals, when cultivation was already negative.

The levels of isavuconazole were measured by liquid chromatography with tandem mass spectrometry (LC-MS/MS) with electrospray ionization (ESI) operated in positive ion mode. The scan type used dynamic multiple reaction monitoring (MRM). We used an Agilent Technologies 1290 Infinity II LC system, including an autosampler, binary pumps and a thermostatted column compartment with 6470 Triple Quad (Agilent Technologies, Santa Clara, CA, USA). Our LC-MS/MS method in human plasma has been successfully validated.

Isavuconazole pharmacokinetic parameters in our patient were calculated based on isavuconazole dosing and its plasma concentration-time profile by maximum a posteriori estimation using the Bayesian approach within Monolix Suite software version 2021R1 (Lixoft SAS, Antony, France). One-compartmental model with first-order elimination best fits the concentration-time data. Model was parametrized in terms of Vd and clearance (CL). Initial (a priori) estimates were adopted from previous pharmacokinetic study in solid-organ transplant recipients (Vd = 338 ± 458 L, CL = 4.1 ± 2.7 L/h) (Wu et al., 2018). Elimination half-life (t_{1/2}) was calculated as $t_{1/2} = \ln 2 \times Vd / CL$.

Calculated isavuconazole Vd, CL and t_{1/2} in our patient are 1014.9 L, 4.43 L/h and 158.8 h, respectively.

Discussion and Conclusion

The summary of product characteristics does not explicitly state the elimination half-life of isavuconazole, and pharmacokinetic data in the literature are also relatively sparse. Multiple-dose pharmacokinetic study of isavuconazole after intravenous and oral administration in healthy volunteers states mean half-life of 84.5–117 hours (Schmitt-Hoffmann et al., 2006). From the mean Vd and CL values in the solid-organ transplant recipients (Wu et al., 2018), a half-life of only 57 hours can be calculated. However, the high variability of Vd and CL in this population (coefficient of variation of 135% and 66%, respectively) suggests that the individual elimination half-life values must also oscillate considerably around the mean. This is also confirmed by the half-life value of almost 160 hours observed in our patient. Such a long half-life implies that after initiation of therapy, steady-state levels will not be reached until after about 30 days. However, in clinical practice, drug levels are usually measured much earlier after initiation of therapy, and unless the level measurement is accompanied by a pharmacokinetic simulation of the time course of drug levels, and unless the long half-life phenomenon is taken into account, the dose of isavuconazole may be hastily adjusted on the basis of the early measured level. This is also seen in our case (Figure 1), where the maintenance dose of 200 mg once daily was increased to threefold based on the subtherapeutic level measured on day 14 of therapy. However, this was not yet a steady-state level and with the dosage increased to 600 mg/day, this dose had to be reduced again on day 27 of therapy as the level approached the threshold for toxicity.

It is also worth mentioning the high Vd, which in our patient was approximately twice the average value reported in the *Summary of Product Characteristics* (EMA, 2015). In such patients, it may then be useful to prolong the administration of the loading dose (200 mg every 8 hours) from two to at least three days for rapid achievement of the pharmacokinetic/pharmacodynamic (PK/PD) target.

In conclusion, based on this case report, we would like to point out the need for TDM of isavuconazole, not only in the sense of measuring the level, but also its

interpretation by pharmacokinetic simulations according to the principles of best practice in TDM.

References

- Desai, A. V., Kovanda, L. L., Hope, W. W., Andes, D., Mouton, J. W., Kowalski, D. L., Townsend, R. W., Mujais, S., Bonate, P. L. (2017) Exposure-response relationships for isavuconazole in patients with invasive aspergillosis and other filamentous fungi. *Antimicrob. Agents Chemother.* **61(12)**, e01034-17.
- EMA (2015) *Cresemba: Summary of Product Characteristics*. Available at: https://www.ema.europa.eu/en/documents/product-information/cresemba-epar-product-information_en.pdf
- EUCAST (2020) Breakpoint tables for interpretation of MICs for antifungal agents. Version 10.0. Available at: https://www.eucast.org/fileadmin/src/media/PDFs/EUCAST_files/AFST/Clinical_breakpoints/AFST_BP_v10.0_200204_updatd_links_200924.pdf
- Furfaro, E., Signori, A., Di Grazia, C., Dominiotto, A., Raiola, A. M., Aquino, S., Ghiggi, C., Ghiso, A., Ungaro, R., Angelucci, E., Viscoli, C., Mikulska, M. (2019) Serial monitoring of isavuconazole blood levels during prolonged antifungal therapy. *J. Antimicrob. Chemother.* **74(8)**, 2341–2346.
- Marty, F. M., Ostrosky-Zeichner, L., Cornely, O. A., Mullane, K. M., Perfect, J. R., Thompson, G. R. 3rd, Alangaden, G. J., Brown, J. M., Fredricks, D. N., Heinz, W. J., Herbrecht, R., Klimko, N., Klyasova, G., Maertens, J. A., Melinkeri, S. R., Oren, I., Pappas, P. G., Racil, Z., Rahav, G., Santos, R., Schwartz, S., Vehreschild, J. J., Young, J. H., Chetchotisakd, P., Jaruratanasirikul, S., Kanj, S. S., Engelhardt, M., Kaufhold, A., Ito, M., Lee, M., Sasse, C., Maher, R. M., Zeiher, B., Vehreschild, M. J. G. T.; VITAL and FungiScope Mucormycosis Investigators (2016) Isavuconazole treatment for mucormycosis: A single-arm open-label trial and case-control analysis. *Lancet Infect. Dis.* **16(7)**, 828–837.
- Monforte, A., Los-Arcos, I., Martin-Gomez, M. T., Campany-Herrero, D., Sacanell, J., Berastegui, C., Marquez-Algaba, E., Sempere, A., Nuvials, X., Deu, M., Castells, L., Moreso, F., Bravo, C., Gavaldà, J., Len, O. (2022) Safety and effectiveness of isavuconazole treatment for fungal infections in solid organ transplant recipients (ISASOT study). *Microbiol. Spectr.* **10(1)**, e0178421.
- Pappas, P. G., Alexander, B. D., Andes, D. R., Hadley, S., Kauffman, C. A., Freifeld, A., Anaissie, E. J., Brumble, L. M., Herwaldt, L., Ito, J., Kontoyannis, D. P., Lyon, G. M., Marr, K. A., Morrison, V. A., Park, B. J., Patterson, T. F., Perl, T. M., Oster, R. A., Schuster, M. G., Walker, R., Walsh, T. J., Wannemuehler, K. A., Chiller, T. M. (2010) Invasive fungal infections among organ transplant recipients: Results of the Transplant-Associated Infection Surveillance Network (TRANSNET). *Clin. Infect. Dis.* **50(8)**, 1101–1111.
- Schmitt-Hoffmann, A., Roos, B., Maeres, J., Heep, M., Spickerman, J., Weidekamm, E., Brown, T., Roehrl, M. (2006) Multiple-dose pharmacokinetics and safety of the new antifungal triazole BAL4815 after intravenous infusion and oral administration of its prodrug, BAL8557, in healthy volunteers. *Antimicrob. Agents Chemother.* **50(1)**, 286–293.
- Wu, X., Clancy, C. J., Rivosecchi, R. M., Zhao, W., Shields, R. K., Marini, R. V., Venkataramanan, R., Nguyen, M. H. (2018) Pharmacokinetics of intravenous isavuconazole in solid-organ transplant recipients. *Antimicrob. Agents Chemother.* **62(12)**, e01643-18.