

Successful Treatment of Detachment of the Incision after Al-Ghorab Procedure: A Case Report and Review of Literature

Rifat Burak Ergül¹, Mehmet Akif Ramazanoğlu², Murat Sambel², Sinan Akşit², Murat Dursun¹, Ateş Kadioğlu^{1,2}

¹Department of Urology, Istanbul Faculty of Medicine, Istanbul University, Istanbul, Turkey;

²Department of Urology, Section of Andrology, Istanbul Faculty of Medicine, Istanbul University, Istanbul, Turkey

Received December 31, 2022; Accepted August 17, 2023.

Key words: Al-Ghorab procedure – Priapism – Shunt surgery – Wound infection

Abstract: Al-Ghorab procedure is known as open distal shunt for the treatment of ischemic priapism. In the literature, no information in terms of complications is available in three of fourteen studies. In the remaining eleven studies, complications occurred in five studies only. Here we present a case report describing successful treatment of detachment of the incision after Al-Ghorab procedure.

Mailing Address: Rifat Burak Ergül, MD., Department of Urology, Istanbul Faculty of Medicine, Istanbul University, Topkapi Neighbourhood, Turgut Özal Street No. 118, 34093 Fatih, Istanbul, Turkey; Phone: +90 212 414 20 00; Fax: +90 212 635 85 22; e-mail: rifat-ergul@hotmail.com

<https://doi.org/10.14712/23362936.2023.24>

© 2023 The Authors. This is an open-access article distributed under the terms of the Creative Commons Attribution License (<http://creativecommons.org/licenses/by/4.0>).

Introduction

Priapism is defined as a prolonged penile erection lasting longer than four hours unrelated to sexual interest or stimulation. The incidence of priapism is 0.9/100,000 per year (Eland et al., 2001). Priapism is categorised as *ischemic* (low flow), *stuttering* (recurrent) and *non-ischemic* (high flow).

Ischemic priapism accounts for 95% of the priapism cases and if not treated accordingly, leads within few hours to irreversible changes resulting in permanent erectile dysfunction. First line therapy is intracavernosal aspiration \pm irrigation with 0.9% saline, eventually in combination with pharmacological agents. Penile shunt surgery (PSS) and implantation of a penile prosthesis (IPP) are indicated as a second-line treatment. Types of shunt surgeries are percutaneous distal (corpora-glandular), open distal (corpora-glandular), open proximal (corpora-spongiosal), peno-scrotal decompression and corpora-venous anastomoses/shunts.

Open distal (corpora-glandular) shunt is known as Al-Ghorab procedure and was modified by Burnett. Briefly, Al-Ghorab procedure is 1–2 centimetre (cm) long transverse incision approximately 1 cm distally from the dorsal coronal margin of the glans penis. The distal end parts of the tunica albuginea underneath

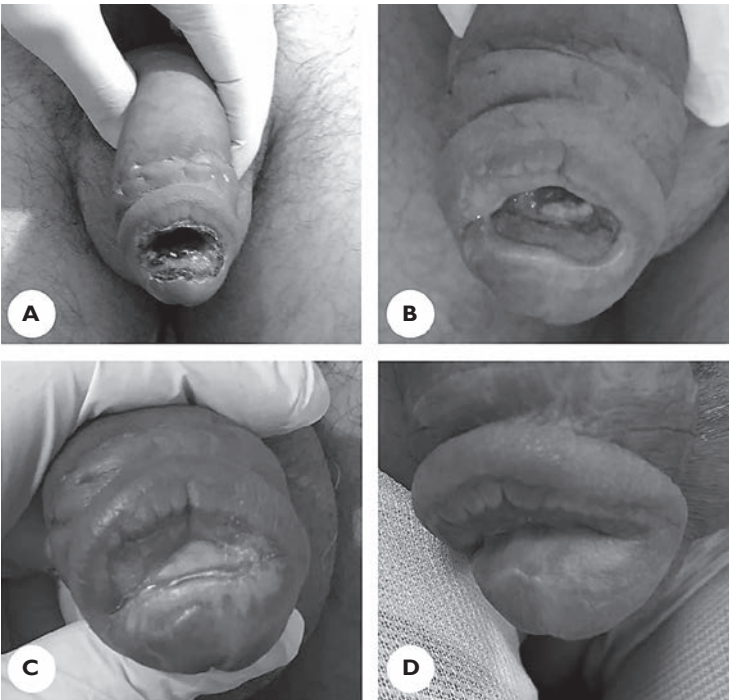


Figure 1 – A) Detachment of the incision on the glans; B) follow-up on the 15th day; C) follow-up on the fourth month; D) local finding before glansplasty.

the incision are excised bilaterally and a corpora-glandular shunt is created (Burnett's modification instead of tunica albuginea excision uses Hegar dilators to create communication between the corpora cavernosa and the glans). The penis is manually compressed from proximal to distal and the accumulated blood in corpora cavernosa is completely drained until fresh blood is obtained. The operation is completed by using 3/0 absorbable sutures to close the skin incision (Muller, 2016).

Case report

A 48-year-old patient without any comorbidity presented for an episode of priapism (after intracavernosal injection of papaverine hydrochloride) lasting for more than 48 hours to an emergency clinic in Iran, where he underwent cavernosal aspiration and saline irrigation with sympathomimetic agent. The priapism episode persisted, and he underwent Al-Ghorab procedure as described above.

Subsequently, the patient was evaluated on the sixth postoperative day at our outpatient clinic after Al-Ghorab procedure. On physical examination detachment of the incision on the glans and foul-smelling discharge were noticed (Figure 1A).

The amoxicillin/clavulanic acid 1,000 mg was administered immediately. After the antibiotic treatment the infection at the detachment side ceased and the patient was scheduled for glans approximation procedure six months after the surgery (Figure 1B and C).

The patient returned six months later from Iran and underwent a glansplasty operation (Figure 1D). The fibrotic tissue at the edges of the wound was removed and the wings of the glans were approximated by means of two-layer fashion. The first layer was approximated by using 4/0 polyglycolic acid and the skin by 4/0 rapid-polyglycolic acid. The histopathological examination of fibrotic tissue revealed fibrosis with inflammatory infiltration. No complications were seen at the postoperative follow-up (Figure 2A).

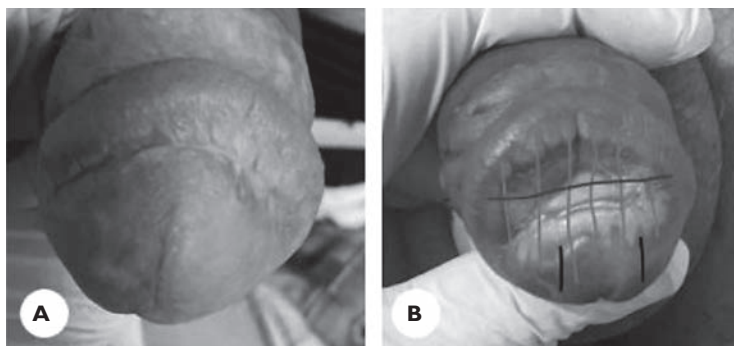


Figure 2 – A) Postoperative second month; B) light grey lines: arteries, dark grey line: Al-Ghorab incision, black line: T-shunt incision.

Table 1 – Studies with Al-Ghorab procedure

	Type of surgery	Number of patients	Number of patients with complications	Type of complications
Ercole et al. (1981)	Al-Ghorab	7	NR	
Segal et al. (2013)	modified Al-Ghorab	10	2	1: wound infection, penile necrosis, urethrocutaneous fistula
Burnett and Pierorazio (2009)	modified Al-Ghorab	3	0	
Teo et al. (2021)	Al-Ghorab	1	0	
Afriansyah et al. (2017)	modified Al-Ghorab	1	NR	
Sekerci et al. (2015)	Al-Ghorab	1	0	
Paladino et al. (2014)	Al-Ghorab	1	1	necrosis distal to the incision, dorsal glandular urethrocutaneous fistula, meatal stenosis
Ford-Glanton et al. (2014)	modified Al-Ghorab	1	1	necrosis, abscess, gangrene
De Stefani et al. (2001)	Al-Ghorab	1	1	urethrocutaneous fistula
Lian et al. (2010)	modified Al-Ghorab	12	0	
Shiraishi and Matsuyama (2013)	modified Al-Ghorab	2	0	
Zheng et al. (2013)	1: Al-Ghorab 2: Al-Ghorab + Grayhack-shunt	1 1	0 1	0 urethral fistula
Nixon et al. (2003)	Al-Ghorab	18	NR	
Ugwumba et al. (2016)	Al-Ghorab	15	0	

NR – not reported

Discussion

Al-Ghorab procedure is one of the shunt surgeries performed as the second line treatment of ischemic priapism. Wound infections, cavernositis, penile skin necrosis, urethrocutaneous fistula, and urethral stricture can develop after Al-Ghorab procedure. There are 14 studies evaluating Al-Ghorab or modified Al-Ghorab

procedure in the literature. In three of fourteen studies, no information in terms of complications is available. In the remaining eleven studies, complications occurred in five of them only (Table 1).

Segal et al. (2013) examined 10 cases treated with modified Al-Ghorab shunt procedure. Wound infection and penile skin necrosis were encountered in two patients after the surgery and one of them developed urethrocutaneous fistula (Segal et al., 2013). The causes of priapism in these two patients were idiopathic and intracavernosal injection of trimix. The patients were treated with surgical debridement.

Paladino et al. (2014) reported necrosis and urethrocutaneous fistula due to Al-Ghorab procedure in a patient who was on valproic acid, clonazepam, haloperidol and levomepromazine for the treatment of schizophrenia. An inadvertent injury of the glandular urethra occurred during the Al-Ghorab procedure. In the follow-up of the patient, necrosis occurred in the distal part of the incision and the patient developed dorsal glandular urethrocutaneous fistula and meatal stenosis on the 14th day after catheter removal. Johanson urethroplasty was performed to treat the fistula.

Ford-Glanton et al. (2014) reported a case of priapism with diabetes mellitus, arterial hypertension, hepatitis C and hyperlipidaemia. The patient complained of fever on admission to the hospital. Leukocytosis ($27,200 \times 10^9/l$) was detected in the blood count. The patient underwent Al-Ghorab procedure and antibiotic treatment for ten days with cephalexin. On the 21st day of the follow-up, thick scar tissue was observed in the glans penis and the wound was considered to have healed properly. However, on the 30th day, the patient presented with complete glans necrosis. After MR (magnetic resonance) imaging, an abscess of approximately 14 cm length was detected spreading to both corpora cavernosa and an emergency distal penectomy was performed. Unlike this case, the patient in our report was on antibiotic treatment for four weeks and he developed no additional penile pathology except wound dehiscence.

De Stefani et al. (2001) reported a case with priapism which was initially treated with Winter procedure. Because of the persistence of priapism episode, Al-Ghorab procedure was performed. The patient developed high flow priapism postoperatively which was treated with the embolization of the cavernosal arteries. Few days later, small, darkened spot appeared on the skin of the glans. Meatal stenosis and urethrocutaneous fistula developed one month later. The fistula was treated with three-layer microsurgical technique and stenosis was managed with self-dilation.

Zheng et al. (2013) reported a urethral fistula in a patient with a priapism episode caused by risperidone. Winter, Al-Ghorab and Grayhack-shunt operations were performed as the surgical treatment of the priapism episode. The urethrocutaneous fistula, which appeared in the early period, closed spontaneously seven months postoperatively.

Al-Ghorab procedure is one of the distal shunts used in the treatment of ischemic priapism with high success rate (80–100%) since 1970s. However, the distal deep arteries which run longitudinally on the glans can be damaged by the transverse incision in this procedure which is subject to complications related to ischemia (Juskiewenski et al., 1982). Wound infection, glans necrosis and gangrene are more likely to occur in Al-Ghorab procedure which can compromise the branches of the deep dorsal artery. Therefore, procedures such as T-shunt, in which an incision parallel to the course of arteries is performed, should be preferred to prevent possible complications (Figure 2B).

Conclusion

Al-Ghorab procedure has a lot of complications such as wound infections, glans necrosis etc. Based on the anatomic localisation of the arteries, T-shunt procedure should be preferred as a management of ischemic priapism not responding to less invasive therapeutic modalities.

References

- Afriansyah, A., Yuri, P., Hutasoit, Y. I. (2017) Intracorporeal dilatation plus Al-Ghorab corporoglandular shunt for salvage management of prolonged ischemic priapism. *Urol. Case Rep.* **12**, 11–13.
- Burnett, A. L., Pierorazio, P. M. (2009) Corporal “snake” maneuver: Corporoglandular shunt surgical modification for ischemic priapism. *J. Sex. Med.* **6**, 1171–1176.
- De Stefani, S., Savoca, G., Ciampalini, S., Stener, S., Gattuccio, I., Belgrano, E. (2001) Urethrocuteaneous fistula as a severe complication of treatment for priapism. *BJU Int.* **88**, 642–643.
- Eland, I. A., van der Lei, J., Stricker, B. H., Sturkenboom, M. J. (2001) Incidence of priapism in the general population. *Urology* **57**, 970–972.
- Ercole, C. J., Pontes, J. E., Pierce, J. M. Jr. (1981) Changing surgical concepts in the treatment of priapism. *J. Urol.* **125**, 210–211.
- Ford-Glanton, B. S., Patel, P., Siddiqui, S. (2014) Penile gangrene with abscess formation after modified Al-Ghorab shunt for idiopathic ischemic priapism. *Case Rep. Urol.* **2014**, 705417.
- Juskiewenski, S., Vaysse, P., Moscovici, J., Hammoudi, S., Bouissou, E. (1982) A study of the arterial blood supply to the penis. *Anat. Clin.* **4**, 101–107.
- Lian, W., Lv, J., Cui, W., Jin, Z., Liu, T., Li, W., Yuan, Y., Xin, Z. (2010) Al-Ghorab shunt plus intracavernous tunneling for prolonged ischemic priapism. *J. Androl.* **31**, 466–471.
- Muller, A. (2016) Al-Ghorab shunt for priapism. *J. Sex. Med.* **13**, 1279–1284.
- Nixon, R. G., O’Connor, J. L., Milam, D. F. (2003) Efficacy of shunt surgery for refractory low flow priapism: A report on the incidence of failed detumescence and erectile dysfunction. *J. Urol.* **170**, 883–886.
- Paladino, J. R. Jr., Wroclawski, M., Den Julio, A., Teixeira, G. K., Glina, S., Lima Pompeo, A. C. (2014) Urethrocuteaneous fistula post-Al-Ghorab shunt. *Can. Urol. Assoc. J.* **8**, E570–E571.
- Segal, R. L., Readal, N., Pierorazio, P. M., Burnett, A. L., Bivalacqua, T. J. (2013) Corporal Burnett “Snake” surgical maneuver for the treatment of ischemic priapism: Long-term followup. *J. Urol.* **189**, 1025–1029.
- Sekerci, C. A., Akbal, C., Sener, T. E., Sahan, A., Sahin, B., Baltacioglu, F., Simsek, F. (2015) Resistant pediatric priapism: A real challenge for the urologist. *Can. Urol. Assoc. J.* **9**, E562–E564.
- Shiraishi, K., Matsuyama, H. (2013) Salvage management of prolonged ischemic priapism: Al-Ghorab shunt plus cavernous tunneling with blunt cavernosotomy. *J. Sex. Med.* **10**, 599–602.

- Teo, J. S. M., Lee, H. J., Yuen, J. S. P. (2021) Perioperative anticoagulation and open distal corpora cavernosa shunt in the management of a case of stuttering idiopathic persistent childhood ischaemic priapism. *Asian J. Urol.* **8**, 436–439.
- Ugwumba, F. O., Ekwedigwe, H. C., Echetaabu, K. N., Okoh, A. D., Nnabugwu, I., Ugwuudu, E. S. (2016) Ischemic priapism in South-East Nigeria: Presentation, management challenges, and aftermath issues. *Niger. J. Clin. Pract.* **19**, 207–211.
- Zheng, D. C., Yao, H. J., Zhang, K., Xu, M. X., Chen, Q., Chen, Y. B., Cai, Z. K., Lu, M. J., Wang, Z. (2013) Unsatisfactory outcomes of prolonged ischemic priapism without early surgical shunts: Our clinical experience and a review of the literature. *Asian J. Androl.* **15**, 75–78.