

# Prague Medical REPORT

(Sborník lékařský)

Multidisciplinary Biomedical Journal  
of the First Faculty of Medicine,  
Charles University

Vol. 120 (2019) No. 4

## Primary Scientific Studies

Immunolocalization of Gas7 in the Subgranular Zone of Mice Hippocampus / Kumar U. page 117

## Case Reports

Attenuated Type of Asphyxiating Thoracic Dysplasia due to Mutations in *DYNC2H1* Gene / Čechová A., Baxová A., Zeman J., Lambert L., Honzík T., Leiská A., Čunát V., Tesařová M. page 124

Transverse Myelitis and Guillain-Barré Syndrome Overlap Secondary to *Bartonella henselae*: Case Report / Rissardo J. P., Caprara A. L. F. page 131

A Single Small Bowel Hemangioma Detected by Video Capsule Endoscopy in a Patient Presenting with Iron-deficiency Anemia – Two Case Reports / Grgić D., Prijic R., Romić I., Augustin G., Markoš P., Korša L., Marušić Z., Rustemović N., Krznarić Ž. page 138

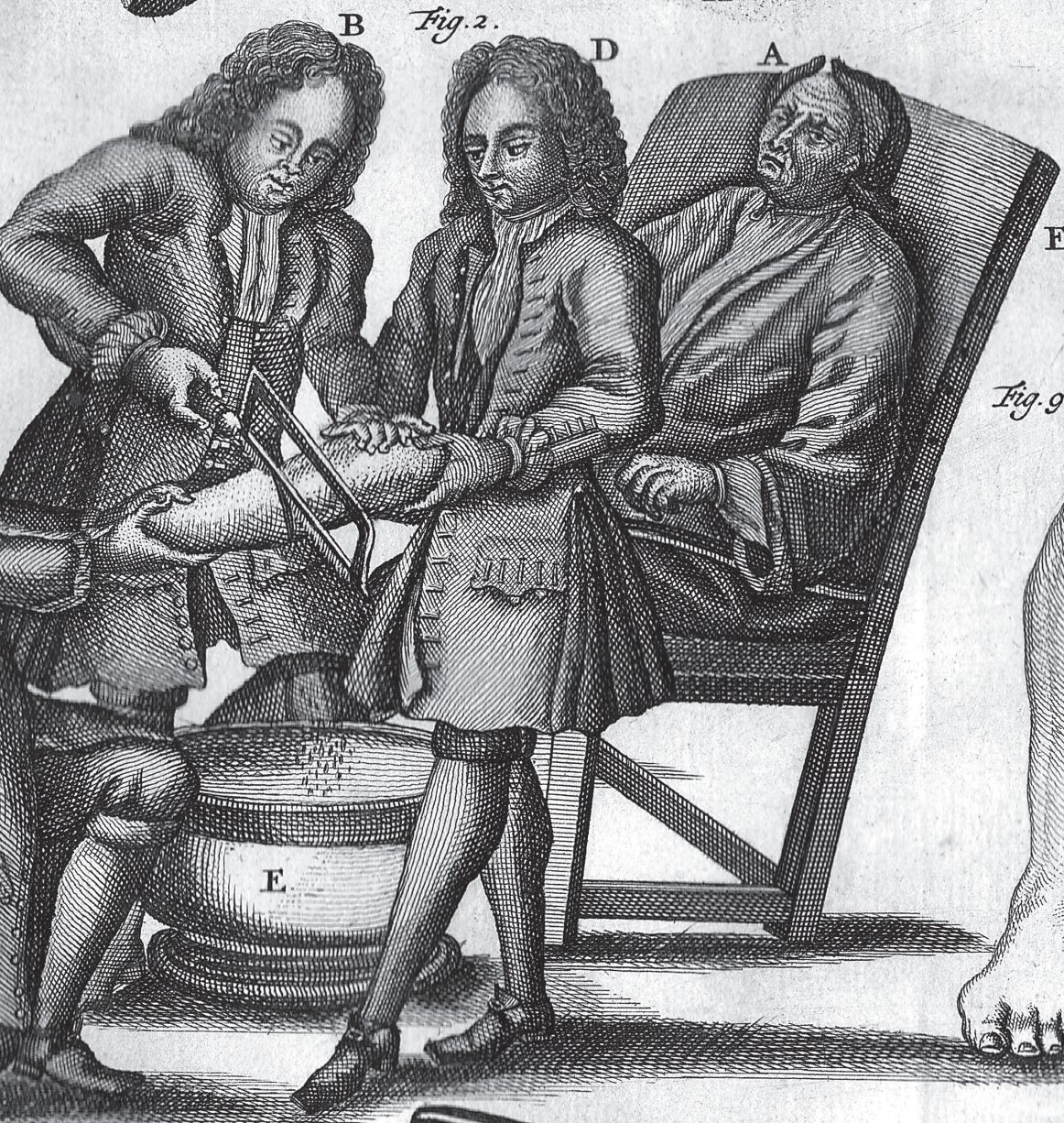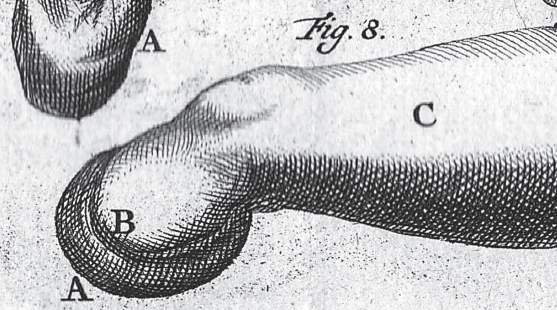
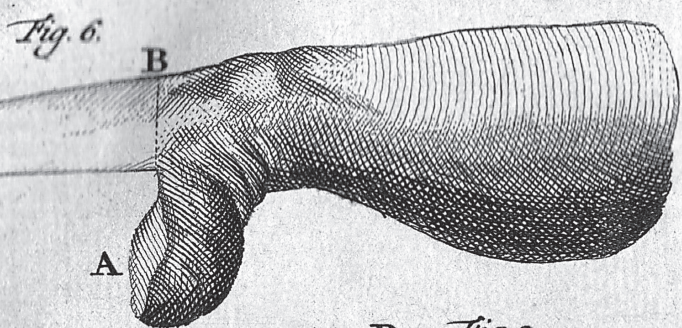

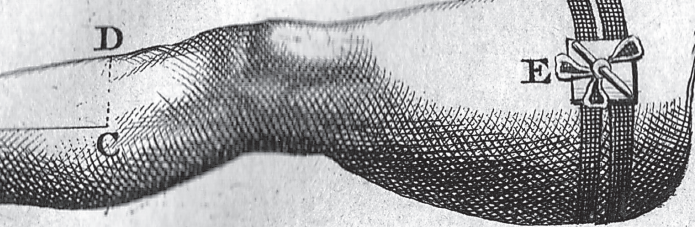
Gossypiboma: A Dramatic Result of Human Error, Case Report and Literature Review / Arıkan Y., Ozdemir O., Seker K. G., Eksi M., Guner E., Kalfazade N., Sahin S., Tasci A. I. page 144

**Instructions to Authors** page 150

**Annual Contents** page 154

**Annual Nominal Index** page 156

**Annual Referee Index** page 157



**Prague Medical Report (Prague Med Rep) is indexed and abstracted by Index-medicus, MEDLINE, PubMed, CNKI, DOAJ, EBSCO, and Scopus.**

**Abstracts and full-texts of published papers can be retrieved from the World Wide Web (<https://pmr.lf1.cuni.cz>).**

# Immunolocalization of Gas7 in the Subgranular Zone of Mice Hippocampus

**Udaya Kumar**

Unit of Biochemistry, Department of Zoology, University of Madras, Chennai,  
Tamil Nadu, India

Received July 17, 2019; Accepted December 1, 2019.

**Key words:** Gas7 – Neural progenitor cell – Differentiation – Subgranular zone

**Abstract:** It is established that neural stem cells (NSC) reside in the hippocampal subgranular zone (SGZ) and contribute to neurogenesis throughout life. Although the molecular events that regulate hippocampal neural stem cell differentiation are known, the precise mechanism is undefined. Here, the role of growth arrest specific 7 (Gas7) protein in SGZ neural progenitor cell differentiation was studied. Immunoblotting and immunohistochemistry for Gas7 were performed on 12 weeks old mice hippocampus. The results displayed a strong signal for Gas7 protein in the mice hippocampal tissue and SGZ cells, therefore suggesting that Gas7 might have a role in neural progenitor cell differentiation in SGZ.

**Mailing Address:** Udaya Kumar, MSc., PhD., Department of Neurology, University of California Los Angeles, 710 Westwood Plaza, Suite 2253, Los Angeles, California 90095, USA; Phone: +1 (309) 533 88 33; e-mail: udevaraj@mednet.ucla.edu

<https://doi.org/10.14712/23362936.2019.16>

© 2019 The Author. This is an open-access article distributed under the terms of the Creative Commons Attribution License (<http://creativecommons.org/licenses/by/4.0>).

## Introduction

Growth arrest-specific genes (Gas) were first discovered in growth arrested cultured cells (Schneider et al., 1988). Individual Gas gene is shown to involve in a variety of biological process that regulates apoptosis (Fabbretti et al., 1995), cytoskeleton arrangement (Brancolini et al., 1992), receptor tyrosine kinase activity (Del Sal et al., 1994), cell cycle control (Li et al., 1996), and nerve cell growth (Adlkofer et al., 1995). Studies from our laboratory and other laboratories have demonstrated that one of the Gas genes, Gas7 have a specialized role in neuronal development (Ju et al., 1998; Moorthy et al., 2005). Reports suggest that Gas7 plays an important role in neuritogenesis and neuronal migration (Chao et al., 2003). In 1998, Ju et al. have reported that inhibiting Gas7 gene prevents neurite outgrowth in Purkinje cells. Conversely, over-expression of Gas7 has been shown to promote neurite extension in Neuro2A and PC12 cells (Chao et al., 2003).

Neurogenesis is an important mechanism for brain development (Pan et al., 2013). In the hippocampus, the subgranular zone (SGZ) continuously produces new neurons (Kumar and Devaraj, 2012). In the SGZ, neural stem cells (NSC) proliferate into progenitor cells (Warner-Schmidt and Duman, 2006). The progenitor cells differentiate into neurons and integrate into the hippocampal circuitry (Warner-Schmidt and Duman, 2006; Kumar et al., 2012). Hippocampal neurogenesis involves in memory formation and plays a critical role in mood regulation (Warner-Schmidt and Duman, 2006).

Though, there is progress in characterizing the neurotransmitters and trophic factors that regulate neural progenitor cell differentiation in SGZ (Gage, 2000; Hagg, 2009) the precise mechanism is yet to be defined. Much less is known about the intracellular cascades that influence neural progenitor cell differentiation in SGZ. Improved comprehension of the mechanisms involved in neural progenitor cell differentiation is thus of major importance for brain repair. In this study, the role of Gas7 in neural progenitor cell differentiation was investigated. The data suggests that Gas7 may be an important determinant for neural progenitor cell differentiation in SGZ.

## Material and Methods

### *Animals*

This study consisted of twelve male Swiss albino mice (12 weeks old), where six mice were used for immunoblotting and remaining for immunohistochemistry. They were obtained from Kings Institute of Preventive Medicine, Chennai, India. Mice were housed on a 12:12 hour light-dark cycle with free access to food and water. All procedures were performed in accordance to the laws and conditions of The Committee for the Purpose of Control and Supervision of Experiments on Animals in India (CPCSEA) and Institutional Animal Ethics Committee (IAEC) guidelines.

### *Immunohistochemistry*

Mice were deeply anesthetized by intraperitoneal injection of sodium pentobarbital (100 mg/kg) and perfused through the ascending aorta for 30 minutes with cold saline and 4% paraformaldehyde. Brains were dissected and stored in the same fixative overnight at 4 °C. 8 µm thick coronal sections containing dorsal hippocampal formation were dewaxed in xylene and rehydrated in a series of ethanol solution. Endogenous peroxidase activity was blocked using 3% hydrogen peroxide and non-specific binding was blocked with 3% bovine serum albumin in phosphate-buffered saline for 60 minutes. The sections were incubated overnight at 4 °C with the Gas7 antibody (dilution 1:200, rabbit anti-Gas7 antiserum was generated against histidine-tagged full-length Gas7 protein expressed in *Escherichia coli* from plasmid pET15b, a kind gift from Dr. Sue Lin-Chao, Academia Sinica, Taiwan). Slides were washed with phosphate-buffered saline and incubated with horse anti-rabbit biotinylated secondary antibody (BA-1100, Vector Labs) for 2 hours at room temperature. They were developed with 3,3'-diaminobenzidine solution and were visualized using Axioskop-2 Plus Phase Contrast Microscope (Carl Zeiss). Negative controls included substituting the primary antibody with 3% bovine serum albumin, which resulted in negative staining.

### *Immunoblot*

Fresh hippocampal tissues were homogenized by an ultrasonic disruption in ice-cold RIPA buffer (R0278, Sigma-Aldrich) containing protease and phosphatase inhibitors (5892970001 and 4906845001, Roche). After centrifugation, the protein level in the supernatant was determined using Micro BCA protein assay kit (23235, Thermo Scientific) with bovine serum albumin as the standard. The proteins were separated by sodium dodecyl sulphate-polyacrylamide gel electrophoresis and were electrophoretically transferred to PVDF membrane (10600023, Amersham Biosciences). The membranes were stained with Ponceau S solution to evaluate the protein transfer. They were later blocked in 5% milk-Tris-buffered saline-Tween and were incubated with Gas7 (dilution 1:1000) and corresponding secondary antibody. The immunoblots were developed using ECL solution and chemiluminescent-compatible film (RPN2232 and 28906835, Amersham Biosciences).

## **Results**

### *Detection of Gas7 in the hippocampal tissue*

Immunoblot analysis of extracts prepared from 12 weeks old mice hippocampus showed positive immunoreactivity for Gas7 in the above stage. Expression of 48 kDa Gas7 protein indicates that Gas7 is physiologically present in the hippocampal tissue (Figure 1).

### *Localization of Gas7 in the subgranular zone cells*

Immunohistochemical analysis of mice hippocampal dentate gyrus showed a high degree of positive immunostaining for Gas7 in the stem cell-rich subgranular zone.

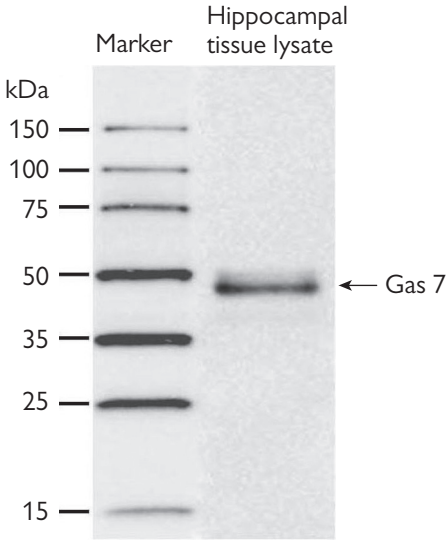


Figure 1 – Immunoblot analysis of mice hippocampal tissue lysate. A single 48 kDa Gas7 protein band was observed.

The signal for Gas7 was prominent in the cytoplasm of subgranular zone cells that indicates Gas7 has a vital role in these cells. A few cells in the granular cell layer also displayed immunoreactivity for Gas7, but their function in granular cells is unclear at this stage (Figure 2).

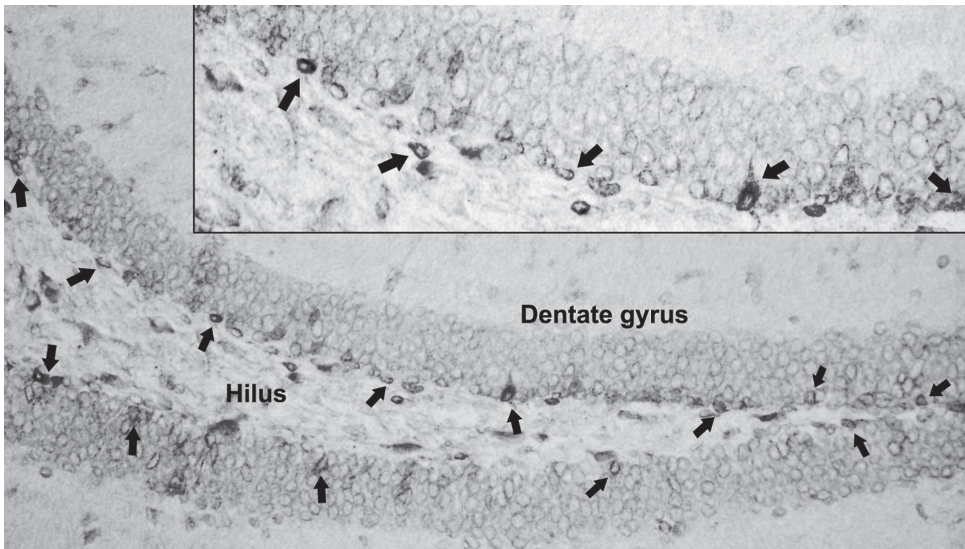


Figure 2 – Immunohistochemical staining of Gas7 in the mice hippocampal dentate gyrus. Gas7 is present in the SGZ of the dentate gyrus (arrow). Upper inset: magnified view of the dentate gyrus showing strong cytosolic localization of Gas7 in the SGZ cells (arrows).



## Discussion

Gas7 expresses in various regions of the brain such as cerebral cortex, cerebellum, hippocampus and plays critical role in brain development (Ju et al., 1998). In particular, Gas7 induces neurite outgrowth. Report by Hung et al. (2011) shows that Gas7 regulates mesenchymal stem cell differentiation. This implies that Gas7 has a role in cell differentiation process. In the previous report, our laboratory has proved that Gas7 facilitates embryonic cell mobility via cytoskeletal reorganization (Moorthy et al., 2005), which shows that Gas7 could interact with cytoskeleton to promote cell migration. These facts indicate that Gas7 might help in cell differentiation by modulating the cytoskeletons.

Numerous studies have shown that cytoskeletons play a major role in cell differentiation (Yourek et al., 2007). Reports suggest actin and microtubules form a protein network in the cell cytoplasm and generate a force that makes cell to differentiate. Disrupting this cytoskeletal network would weaken the cell membrane elasticity, leading to failure of cell differentiation (Fletcher and Mullins, 2010). Previous studies on Gas7 shows that Gas7 interacts with actin and microtubules. It plays a crucial role in actin assembly and microtubule stabilization (She et al., 2002; Uchida et al., 2009). In the present study, a strong signal for Gas7 protein in the hippocampal tissue lysate was noticed. Immunohistochemistry data confirms Gas7 accumulation in the cytoplasm of SGZ cells. The localization of the Gas7 protein in the hippocampal neurogenic niche suggests that Gas7 might have a role in SGZ neural progenitor cell differentiation. The precise mechanism of SGZ progenitor cell differentiation by Gas7 is unclear at this stage. However, one mechanism where Gas7 might aid in cell differentiation is through cytoskeletal reorganization. Gas7 may help to form stress fibers in the cell cytoplasm by cross-linking actin

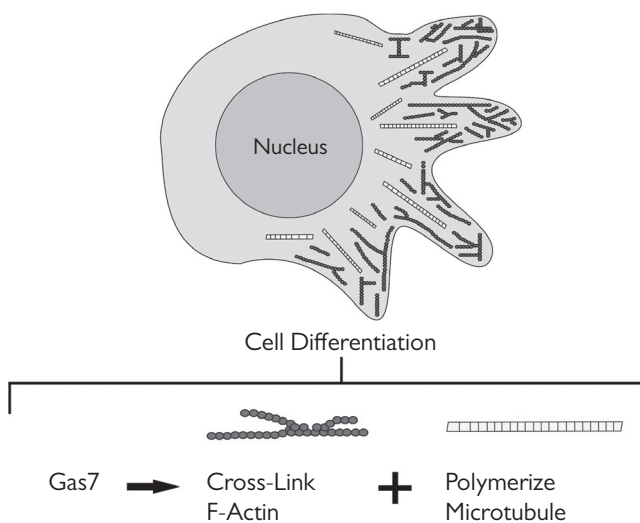


Figure 3 – Schematic representation of cytoskeleton mediated neural progenitor cell differentiation. Gas7 cross-links F-actin and aids in the polymerization of microtubules. This process within the cell encourages to change its morphology and differentiate.

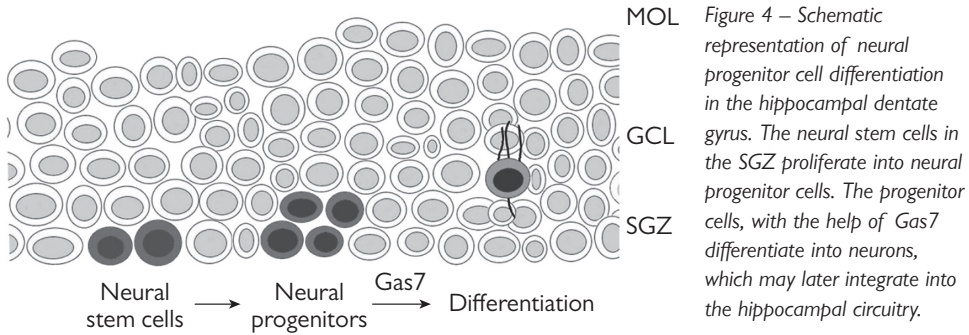


Figure 4 – Schematic representation of neural progenitor cell differentiation in the hippocampal dentate gyrus. The neural stem cells in the SGZ proliferate into neural progenitor cells. The progenitor cells, with the help of Gas7 differentiate into neurons, which may later integrate into the hippocampal circuitry.

filaments and polymerizing microtubules. The stress developed due to the change in cytoskeletal structure could induce the cell to change its morphology, leading to cell differentiation (Figures 3 and 4). Further investigation on Gas7 is needed to resolve the mechanism of Gas7 mediated SGZ neural progenitor cell differentiation. Understanding the functional role of SGZ neural progenitor cell differentiation as well as its underlying cellular and molecular substrates will enable us to identify potential interventions with hippocampal diseases and develop targeted therapies for memory-related disorders.

*Acknowledgements: The author thanks Divya Chandrababu and Vahin Uday for their support.*

## References

- Adlkofer, K., Martini, R., Aguzzi, A., Zielasek, J., Toyka, K. V., Suter, U. (1995) Hypermyelination and demyelinating peripheral neuropathy in Pmp22-deficient mice. *Nat. Genet.* **11**, 274–280.
- Brancolini, C., Bottega, S., Schneider, C. (1992) Gas2, a growth arrest-specific protein, is a component of the microfilament network system. *J. Cell Biol.* **117**, 1251–1261.
- Chao, C. C., Su, L. J., Sun, N. K., Ju, Y. T., Lih, J. C., Chao, S. L. (2003) Involvement of Gas7 in nerve growth factor-independent and dependent cell processes in PC12 cells. *J. Neurosci. Res.* **74**, 248–254.
- Del Sal, G., Collavin, L., Ruaro, M. E., Edomi, P., Saccone, S., Valle, G. D., Schneider, C. (1994) Structure, function, and chromosome mapping of the growth-suppressing human homologue of the murine Gas1 gene. *Proc. Natl. Acad. Sci. U. S. A.* **91**, 1848–1852.
- Fabbretti, E., Edomi, P., Brancolini, C., Schneider, C. (1995) Apoptotic phenotype induced by overexpression of wild-type Gas3/PMP22: Its relation to the demyelinating peripheral neuropathy CMT1A. *Genes Dev.* **9**, 1846–1856.
- Fletcher, D. A., Mullins, R. D. (2010) Cell mechanics and the cytoskeleton. *Nature* **463**, 485–492.
- Gage, F. H. (2000) Mammalian neural stem cells. *Science* **287**, 1433–1438.
- Hagg, T. (2009) From neurotransmitters to neurotrophic factors to neurogenesis. *Neuroscientist* **15**, 20–27.
- Hung, F. C., Chang, Y., Chao, S. L., Chao, C. C. (2011) Gas7 mediates the differentiation of human bone marrow-derived mesenchymal stem cells into functional osteoblasts by enhancing Runx2-dependent gene expression. *J. Orthop. Res.* **29**, 1528–1535.

- Ju, Y. T., Chang, A. C., She, B. R., Tsaur, M. L., Hwang, H. M., Chao, C. C., Cohen, S. N., Chao, S. L. (1998) Gas7: A gene expressed preferentially in growth-arrested fibroblasts and terminally differentiated Purkinje neurons affects neurite formation. *Proc. Natl. Acad. Sci. U. S. A.* **95**, 11423–11428.
- Kumar, D. U., Devaraj, H. (2012) Expression of Wnt 3a,  $\beta$ -catenin, cyclin D1 and PCNA in mouse dentate gyrus subgranular zone (SGZ): A possible role of Wnt pathway in SGZ neural stem cell proliferation. *Folia Biol. (Praha)* **58**, 115–120.
- Kumar, D. U., Nagaraj, R., Devaraj, H. (2012) Immunolocalization of Notch1, Hes1 and NF-kB in the murine hippocampal subgranular zone (SGZ): Possible role of the Notch pathway in the maintenance of the SGZ neural stem cell population. *Neurophysiology* **44**, 208–215.
- Li, R., Chen, J., Hammonds, G., Phillips, H., Armanini, M., Wood, P., Bunge, R., Godowski, P. J., Sliwkowski, M. X., Mather, J. P. (1996) Identification of Gas6 as a growth factor for human Schwann cells. *J. Neurosci.* **16**, 2012–2019.
- Moorthy, P. P., Kumar, A. A., Devaraj, H. (2005) Expression of the Gas7 gene and Oct4 in embryonic stem cells of mice. *Stem Cells Dev.* **14**, 664–670.
- Pan, Y. W., Wang, W., Xia, Z. (2013) Assessment of adult neurogenesis in mice. *Curr. Protoc. Toxicol.* **12**, 12–20.
- Schneider, C., King, R. M., Philipson, L. (1988) Genes specifically expressed at growth arrest of mammalian cells. *Cell* **54**, 787–793.
- She, B. R., Liou, G. G., Chao, S. L. (2002) Association of the growth-arrest-specific protein Gas7 with F-actin induces reorganization of microfilaments and promotes membrane outgrowth. *Exp. Cell Res.* **273**, 34–44.
- Uchida, T., Akiyama, H., Sakamoto, W., Koga, T., Yan, K., Uchida, C., Hirose, K., Itoh, T. J. (2009) Direct optical microscopic observation of the microtubule polymerization intermediate sheet structure in the presence of Gas7. *J. Mol. Biol.* **391**, 849–857.
- Warner-Schmidt, J. L., Duman, R. S. (2006) Hippocampal neurogenesis: Opposing effects of stress and antidepressant treatment. *Hippocampus* **16**, 239–249.
- Yourek, G., Hussain, M. A., Mao, J. J. (2007) Cytoskeletal changes of mesenchymal stem cells during differentiation. *ASAIO J.* **53**, 219–228.

# Attenuated Type of Asphyxiating Thoracic Dysplasia due to Mutations in *DYNC2H1* Gene

**Anna Čechová<sup>1</sup>, Alice Baxová<sup>2</sup>, Jiří Zeman<sup>1</sup>, Lukáš Lambert<sup>3</sup>, Tomáš Honzík<sup>1</sup>, Alena Leiská<sup>3</sup>, Václav Čunát<sup>4</sup>, Markéta Tesařová<sup>1</sup>**

<sup>1</sup>Department of Pediatrics and Adolescent Medicine, First Faculty of Medicine, Charles University and General University Hospital in Prague, Prague, Czech Republic;

<sup>2</sup>Institute of Biology and Medical Genetics, First Faculty of Medicine, Charles University and General University Hospital in Prague, Prague, Czech Republic;

<sup>3</sup>Department of Radiology, First Faculty of Medicine, Charles University and General University Hospital in Prague, Prague, Czech Republic;

<sup>4</sup>The Institute for the Care of Mother and Child, Prague, Czech Republic

Received July 4, 2019; Accepted December 1, 2019.

**Key words:** Asphyxiating thoracic dysplasia – Chest circumference – *DYNC2H1* gene

**Abstract:** Asphyxiating thoracic dysplasia (ATD) represents a heterogeneous group of skeletal dysplasias with short ribs, narrow chest and reduced thoracic capacity. Mutations in several genes including *IFT80*, *DYNC2H1*, *TTC21B* and *WDR19* have been found in patients with ATD. Both severe and milder course of the disease were described in correlation with secondary involvement of lung's function. Two children with attenuated form of ATD are described. Their anthropometric parameters for birth weight, length and head circumference were normal but narrow thorax was observed in both of them in early infancy with chest circumference  $< -3$  SD (standard deviation) in comparison to age related controls. The postnatal adaptation and development of both children was uneventful except for mild tachypnoea in one of them which persisted till the age of 6 months. In both children, radiographs

*This study was supported by projects of Ministry of Education, Youth, and Sports of the Czech Republic (PROGRES Q32/LF2) and Ministry of Health of the Czech Republic (RVO-VFN 64165/2012).*

**Mailing Address:** Ing. Markéta Tesařová, PhD., Department of Pediatrics and Adolescent Medicine, First Faculty of Medicine, Charles University and General University Hospital in Prague, Ke Karlovu 2, 128 08 Prague 2, Czech Republic; Phone: +420 224 967 748; e-mail: marketa.tesarova@lf1.cuni.cz

<https://doi.org/10.14712/23362936.2019.17>

© 2019 The Authors. This is an open-access article distributed under the terms of the Creative Commons Attribution License (<http://creativecommons.org/licenses/by/4.0>).

revealed narrow upper half of the chest with shorter ribs and atypical configuration of pelvis with horizontally running acetabula and coarse internal edges typical for ATD. Molecular analyses using whole exome sequencing in one family revealed that the patient is compound heterozygote in *DYNC2H1* gene for a frame-shift mutation c.4458delT resulting in premature stop-codon p.Phe1486Leufs\*11 and a missense mutation c.9044A>G (p.Asp3015Gly). The second family refused the DNA analysis. Regular monitoring of anthropometric parameters during childhood is of big importance both in health and disease. In addition, measurement of the chest circumference should be included, at least at birth and during infancy.

## Introduction

Asphyxiating thoracic dysplasia (ATD, Jeune syndrome) is a rare skeletal disease belonging to the large group of ciliopathies, disorders with primary impairment of cilia involved in the transduction of signals in the hedgehog pathway that is especially important in skeletal development (Dagoneau et al., 2009; Huber and Cormier-Daire, 2012).

On the molecular level, ATD represents a heterogeneous group of genetic disorders with mutations in several genes including *IFT80*, *DYNC2H1*, *TTC21B* and *WDR19* (Baujart et al., 2013). On the clinical level, ATD is characterized by short ribs resulting in narrow chest and reduced thoracic capacity, short long bones, inconstant polydactyly, and trident acetabular roof sometimes accompanied by renal, liver and retinal disease (Dagoneau et al., 2009). The course of the disease and the prognosis depend on the severity of ribs shortening with the residual lung function, recurrent lung infections and secondary heart problems (Emiralioglu et al., 2018). Both severe and attenuated forms of ATD were described, but the phenotype may differ even between siblings with the identical mutation in *DYNC2H1* suggesting the impact of some modifier alleles or epigenetic factors (Schmidts et al., 2013a).

We report the results of clinical and radiologic analyses in two children with attenuated type of asphyxiating thoracic dysplasia, in one of them due to mutations in *DYNC2H1*.

## Methods

DNA was extracted from blood samples by Gentra PureGene Blood Kit (Qiagen, USA). Exome sequencing was performed using 1 µg of DNA from patient 1 and both of his parents. For DNA enrichment of barcoded DNA libraries were used SeqCap EZ MedExome Target Enrichment Kit (Roche, USA) according to the manufacturer's protocol. The Illumina HiSeq 2500 system at the Genomic facility in University Hospital Motol was used for DNA sequencing of the captured barcoded DNA library. The resulting FASTQ files were aligned to the Human Genome Reference (hg19) using Novoalign (3.02.10) and processed as described previously (Chaloupka et al., 2018). Mutation identified in *DYNC2H1* (ENSG00000187240, ENST00000398093) was confirmed by Sanger sequencing. Anthropometric

parameters in affected children were compared to large nation-wide anthropological survey of Czech children (Vignerová et al., 2006).

### Ethics

The study was approved by the Ethics Committee of the General University Hospital in Prague and was conducted in agreement with institutional guidelines.

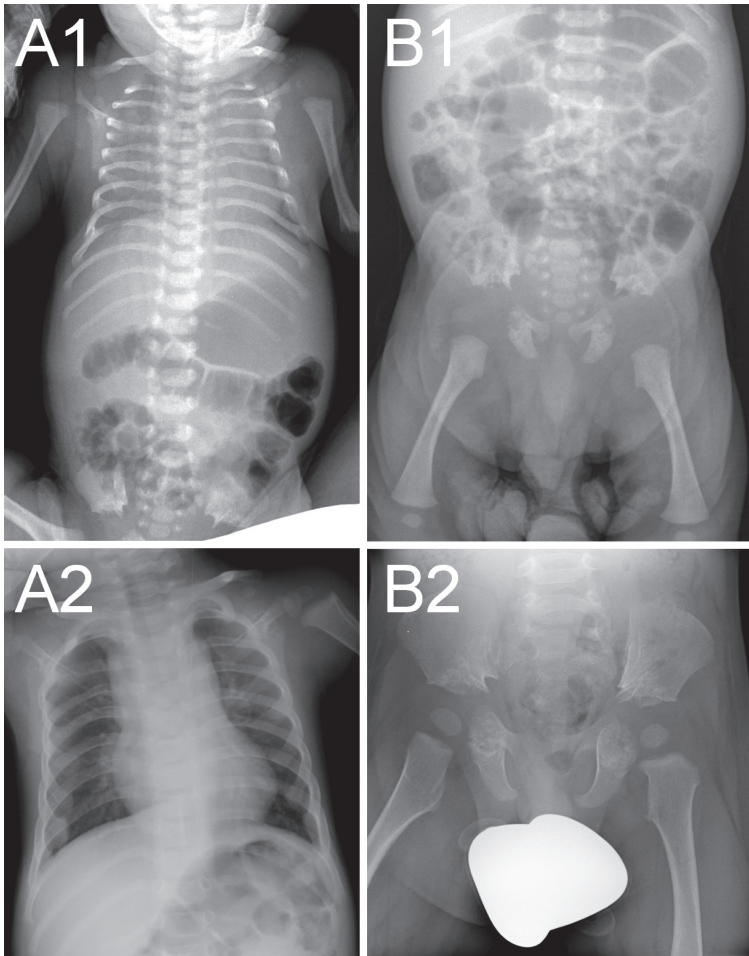


Figure 1 – Radiographs of the chest, pelvis, and hip joints in the boy (patient 1) with asphyxiating thoracic dysplasia due to heterozygous mutations *c.4458delT* (p.Phe1486Leufs\*11) and *c.9044A>G* (p.Asp3015Gly) in *DYNC2H1* gene at the age of 10 days (A1, B1) and 6 months (A2, B2). The rib cage is narrowed and elongated, ribs are shortened, running horizontally, their anterior ends are widened. The collar bones are positioned higher (A1, A2). The pelvis is dysplastic, iliac bones rounded, acetabular roofs are horizontal with pointed medial margins (B1, B2). The sciatic and pubic bones are shortened, sturdy with uneven widening at their junction. Both femoral necks are sturdy. Femoral heads have normal appearance and position, and there is a mild medial bowing of the diaphysis of both femurs.

In members of family 1, written informed consent for molecular analyses was obtained. The families have agreed with use of the results including relevant clinical data and photographs for publication.

### Patient 1

The parents, grandparents and older sister are healthy. The boy was born at term in the 40<sup>th</sup> week of gestation with birth weight 3,230 g (40<sup>th</sup> percentile), length 48 cm (10<sup>th</sup> percentile), head circumference 34 cm (35<sup>th</sup> percentile) and chest circumference 30.9 cm (−1.4 SD – standard deviation, gestation related controls 33.4±1.9). The postnatal adaptation was uneventful except mild tachypnoea which persisted till the age of 6 months and was explained by boy's narrow thorax. Radiographs of the chest and pelvic girdle suggesting asphyxiating thoracic dysplasia are shown in Figure 1. At the age of 10 months (Figure 2), the boy had weight 8,000 g (8<sup>th</sup> percentile), length 70 cm (10<sup>th</sup> percentile), head circumference 45 cm (25<sup>th</sup> percentile) and chest circumference 40.5 cm (−3.2 SD, age related controls 48.1±2.4). At the age of 18 months, his weight was 10.5 kg (20<sup>th</sup> percentile), length 78.5 cm (10<sup>th</sup> percentile), head circumference 47 cm (25<sup>th</sup> percentile) and chest circumference 43.5 cm (−3.3 SD, age related controls 50.0±1.8). His mental and motor development corresponded to his age and he had no tachypnoea or any other respiratory or heart problems including normal echocardiography.

### Patient 2

The parents and grandparents are healthy. The girl was born in term, but prenatal sonography in the second trimester revealed a disproportionate stature with some shortening of both legs. Her birth weight was 3,300 g (55<sup>th</sup> percentile), length

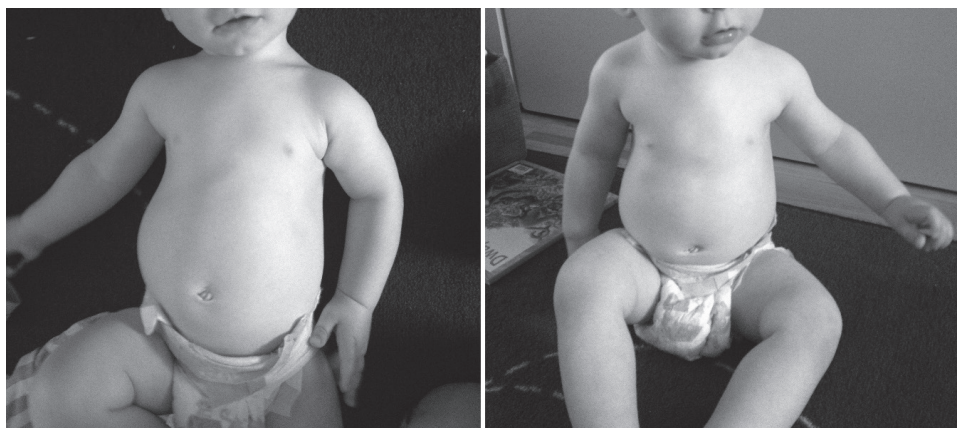

Figure 2 – The 10-months old boy (patient 1) with asphyxiating thoracic dysplasia and narrow chest circumference 40.5 cm (age related controls 46.7 cm) due to heterozygous mutations *c.4458delT* (p.Phe1486Leufs\*11) and *c.9044A>G* (p.Asp3015Gly) in *DYNC2H1* gene.

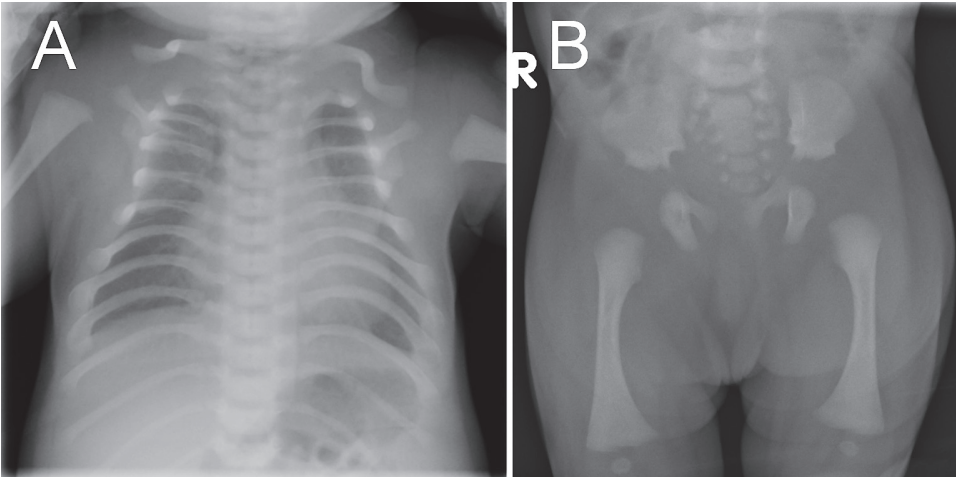


Figure 3 – Radiograph of the chest (A) and pelvis (B) in a 2-months-old girl (patient 2) with asphyxiating thoracic dysplasia. The rib cage is narrow and elongated, ribs are short and horizontal, their anterior ends are widened. The collar bones are positioned higher. The pelvis is dysplastic, iliac bones rounded; acetabular roofs are horizontal with pointed medial margins. The sciatic and pubic bones are shortened, sturdy with uneven widening at their junction. Both femoral necks are sturdy. Femoral heads have normal appearance and position, and there is a mild medial bowing of the diaphysis of both femurs.

47 cm (6.6<sup>th</sup> percentile) and head circumference 34 cm (40<sup>th</sup> percentile). Postnatal adaptation was uneventful, and she gained her weight properly. The results of neurologic investigation and sonography of the brain and kidney were normal. At the age of 2 months, her weight was 4,170 g (30<sup>th</sup> percentile), length 53.5 cm (14<sup>th</sup> percentile), head circumference 36.5 cm (12<sup>th</sup> percentile) but the thorax was narrow with chest circumference 33 cm (–3.1 SD, age related controls 39.0±1.6). Radiographs of the chest and pelvic girdle in the girl were compatible with the diagnosis of asphyxiating thoracic dysplasia (Figure 3). The parents refused the diagnostics on a molecular level. According to the phone contact with the mother, the motor and mental development of the girl is appropriate to her age and she has no respiratory problems.

### Molecular analyses

The molecular analyses in the family 1 using whole exome sequencing revealed that the boy is compound heterozygote for two variants in *DYNC2H1* gene: the frame-shift mutation c.4458delT resulting in premature stop-codon p.Phe1486Leufs\*11 and mutation c.9044A>G (p.Asp3015Gly). Both parents are heterozygotes for one mutation. The maternally inherited mutation c.4458delT in exon 29 has been previously found in patient with short-rib polydactyly syndrome type III (Verma-Naumoff syndrome, MIM# 263510) (Zhang et al., 2018). The second paternally



inherited mutation c.9044A>G in exon 57 has been previously found in several patients with ATD (Dagoneau et al., 2009; Schmidts et al., 2013a).

## Discussion

Ciliary defects arising from mutations in genes encoding ciliary proteins lead to complex developmental disorders in human and other vertebrates, termed ciliopathies (Schmidts et al., 2013b). One type of ciliopathies with skeletal involvement and short ribs with or without polydactyly is represented by a heterogeneous group of diseases including asphyxiating thoracic dysplasia (ATD, Jeune syndrome), Verma-Naumoff syndrome (SRP type III), Majewski syndrome (SRP type II), Ellis-van Creveld syndrome (EVC), the Sensenbrenner syndrome, and Weyers acrofacial dysostosis (Huber and Cormier-Daire, 2012).

Molecular analyses in children with Jeune syndrome revealed mutations in several genes including *DYNC2H1* encoding the cytoplasmic dynein 2 heavy chain 1 involved in the generation and maintenance of cilia (Dagoneau et al., 2009) or genes involved in intraflagellar transport *IFT80*, *IFT122*, *IFT43*, *WDR35*, *WDR19*, *TTC21B* as well as in genes responsible for the basal bodies *NEK1*, *EVC* and *EVC2* (Huber and Cormier-Daire, 2012). Especially mutations in *DYNC2H1* seem to be the major gene responsible for ATD. For example, in the group of 53 patients with ATD including 23 patients and 30 fetuses from 39 families, mutations in *DYNC2H1* was found in 59% of cases (Baujat et al., 2013). Also in one of our patients, mutations in *DYNC2H1* was found including a frame-shift mutation c.4458delT resulting in premature stop-codon p.Phe1486Leufs\*11 (Zhang et al., 2018) and a missense mutation c.9044A>G (p.Asp3015Gly) (Dagoneau et al., 2009; Schmidts et al., 2013a). The parents of the second child with Jeune syndrome from our centre did not admit any eventual health problems in their child and did not agreed with molecular analysis.

Both our children with Jeune syndrome have a mild form of the disease. They are clinically well regardless of very narrow thorax with narrow chest circumference < 3 SD in comparison to healthy age-related controls, but neither of them had any acute severe pulmonary infection, so far.

## Conclusion

Regular monitoring of the weight, length and head circumference during childhood is very important both in health and disease. In addition, measurement of the chest circumference should be included, at least at birth and during infancy.

## References

- Baujat, G., Huber, C., El Hokayem, J., Caumes, R., Do Ngoc Thanh, C., David, A., Delezoide, A. L., Dieux-Coeslier, A., Estournet, B., Francannet, C., Kayirangwa, H., Lacaille, F., Le Bourgeois, M., Martinovic, J., Salomon, R., Sigaudy, S., Malan, V., Munnich, A., Le Merrer, M., Le Quan Sang, K. H., Cormier-Daire, V. (2013) Asphyxiating thoracic dysplasia: Clinical and molecular review of 39 families. *J. Med. Genet.* **50**, 91–98.

- Chaloupka, A., Piherova, L., Grochova, I., Binova, J., Krejci, J., Spinarova, L., Stranecky, V., Kmoch, S., Kubanek, M. (2018) Genetic architecture of recent-onset dilated cardiomyopathy in Moravian region assessed by whole-exome sequencing and its clinical correlates. *Biomed. Pap. Med. Fac. Univ. Palacky Olomouc Czech Repub.* (Epub ahead of print)
- Dagoneau, N., Goulet, M., Genevieve, D., Sznajder, Y., Martinovic, J., Smithson, S., Huber, C., Baujat, G., Flori, E., Tecco, L., Cavalcanti, D., Delezoide, A. L., Serre, V., Le Merrer, M., Munnich, A., Cormier-Daire, V. (2009) DYNC2H1 mutations cause asphyxiating thoracic dystrophy and short rib-polydactyly syndrome, type III. *Am. J. Hum. Genet.* **84**, 706–711.
- Emiralioglu, N., Wallmeier, J., Olbrich, H., Omran, H., Ozcelik, U. (2018) DYNC2H1 mutation causes Jeune syndrome and recurrent lung infections associated with ciliopathy. *Clin. Respir. J.* **12**, 1017–1020.
- Huber, C., Cormier-Daire, V. (2012) Ciliary disorder of the skeleton. *Am. J. Med. Genet. C Semin. Med. Genet.* **160C**, 165–174.
- Schmidts, M., Arts, H. H., Bongers, E. M., Yap, Z., Oud, M. M., Antony, D., Duijckers, L., Emes, R. D., Stalker, J., Yntema, J. B., Plagnon, V., Hoischen, A., Gilissen, C., Forsythe, E., Lausch, E., Veltman, J. A., Roeleveld, N., Superti-Furga, A., Kutkowska-Kazmierczak, A., Kamsteeg, E. J., Elcioglu, N., van Maarle, M. C., Graul-Neumann, L. M., Devriendt, K., Smithson, S. F., Wellesley, D., Verbeek, N. E., Hennekam, R. C., Kayserili, H., Scambler, P. J., Beales, P. L., UK10K, Knoers, N. V., Roepman, R., Mitchison, H. M. (2013a) Exome sequencing identifies DYNC2H1 mutations as a common cause of asphyxiating thoracic dystrophy (Jeune syndrome) without major polydactyly, renal or retinal involvement. *J. Med. Genet.* **50**, 309–323.
- Schmidts, M., Vodopiutz, J., Christou-Savina, S., Cortes, C. R., McInerney-Leo, A. M., Emes, R. D., Arts, H. H., Tuysuz, B., D'Silva, J., Leo, P. J., Giles, T. C., Oud, M. M., Harris, J. A., Koopmans, M., Marshall, M., Elcioglu, N., Kuechler, A., Bockenhauer, D., Moore, A. T., Wilson, L. C., Janecke, A. R., Hurles, M. E., Emmet, W., Gardiner, B., Streubel, B., Dopita, B., Zankl, A., Kayserili, H., Scambler, P. J., Brown, M. A., Beales, P. L., Wicking, C., UK10K, Duncan, E. L., Mitchison, H. M. (2013b) Mutations in the gene encoding IFT dynein complex component WDR34 cause Jeune asphyxiating thoracic dystrophy. *Am. J. Hum. Genet.* **93**, 932–944.
- Vignerová, J., Riedlová, J., Bláha, P., Kobzová, J., Krejčovský, L., Brabec, M., Hrušková, M. (2006) *6<sup>th</sup> Nation-wide Anthropological Survey of Children and Adolescents 2001, Czech Republic.* Faculty of Sciences, Charles University, and the National Institute of Public Health, Prague. (in Czech)
- Zhang, W., Taylor, S. P., Ennis, H. A., Forlenza, K. N., Duran, I., Li, B., Sanchez, J. A. O., Nevarez, L., Nickerson, D. A., Bamshad, M., University of Washington Center for Mendelian Genomics, Lachman, R. S., Krakow, D., Cohn, D. H. (2018) Expanding the genetic architecture and phenotypic spectrum in the skeletal ciliopathies. *Hum. Mutat.* **39**, 152–166.

# Transverse Myelitis and Guillain-Barré Syndrome Overlap Secondary to *Bartonella henselae*: Case Report

**Jamir Pitton Rissardo, Ana Leticia Fornari Caprara**

Department of Medicine and Department of Neurology, Federal University of Santa Maria, Santa Maria, Brasil

Received September 13, 2019; Accepted December 1, 2019.

**Key words:** Transverse myelitis – Guillain-Barré syndrome – Overlap – *Bartonella henselae*

**Abstract:** The GBS/ATM overlap is characterized by the simultaneous occurrence of Guillain-Barré syndrome (GBS) and acute transverse myelitis (ATM), which are two neurological autoimmune disorders. In this context, cat scratch disease (CSD) was rarely reported combined with this overlap. An adult female presenting fever, back pain, inferior limb weakness, and anuria was admitted to our hospital. On the physical exam, a distended bladder and bilateral lymphadenopathy were observed. The neurological assessment revealed muscle weakness, plantar flexion, and hyporeflexia in right with absence in left. Also, she reported hyperalgesia in inferior limbs. Her blood pressure was fluctuating being in the majority of the time hypertensive. A spinal cord MRI (magnetic resonance imaging) was suggestive of transverse myelitis. Methylprednisolone was started. The cerebrospinal fluid showed 37.0 cells/mm<sup>3</sup> of white blood cell count, 49 mg/dl of glucose, and 50.7 mg/dl of protein. Ceftriaxone and vancomycin were started. On further questioning, the subject stated that her finger was bitten by a cat about two weeks before the beginning of the symptoms. Serological tests were positive for *Bartonella henselae*. Doxycycline and rifampin were started. After one-month, her symptoms improve but she continued with a radicular pain and weakness. An EMG (electroneuromyography) was suggestive of demyelination. IVIG (intravenous immunoglobulin) was started. After IVIG 4-day, the patient had recovery of her strength. To the authors' knowledge, there are two case reports of pediatric individuals linking CSD and GBS/ATM. Still, this association in an adult patient has not been reported until the present moment.

**Mailing Address:** Jamir Pitton Rissardo, Rua Roraima, Santa Maria, Rio Grande do Sul, Brasil; Phone: (55) (55) 334 729 08; e-mail: jamirrissardo@gmail.com

<https://doi.org/10.14712/23362936.2019.18>

© 2019 The Authors. This is an open-access article distributed under the terms of the Creative Commons Attribution License (<http://creativecommons.org/licenses/by/4.0>).

## Introduction

The GBS/ATM overlap is characterized by the simultaneous occurrence of Guillain-Barré syndrome (GBS) and acute transverse myelitis (ATM), which are two neurological autoimmune disorders (Guo and Zhang, 2019). Although they could have some similarities, these diseases have different clinical manifestations, histological, and pathological findings (Mao and Hu, 2014). In this context, cat scratch disease (CSD) was rarely reported combined with this overlap. To the authors' knowledge, there are two case reports of pediatric individuals linking CSD and GBS/ATM (Carman et al., 2013; Zakhour et al., 2018). Still, this association in an adult patient has not been reported until the present moment.

## Case report

A 62-year-old female presenting fever, back pain, inferior limb weakness, and anuria within seven days of onset was admitted to our hospital. Her comorbid condition was dyslipidemia, and she was in use of simvastatin 20 mg once a day. Her family history was unremarkable for neurological diseases. On the physical exam, a suprapubic tenderness without guarding or rebound, which was suggestive of a distended bladder; and bilateral cervical (1 cm and 1.5 cm) with axillary (2 cm) lymphadenopathy were observed. The neurological assessment revealed muscle strength in bilateral inferior limbs grade 2 according Medical Research Council scale, plantar flexion, and diminished reflex in right with absence in left. Also, she reported hyperalgesia in inferior limbs. Her blood pressure was fluctuating being in the majority of the time hypertensive. Laboratory tests including urinalysis and urine culture were within normal limits. The subject was attended in the emergency department, and a urinary catheter was inserted, and it drained 1,500 ml of clear urine.

A cranial computed tomography and a brain magnetic resonance imaging (MRI) were normal. A spinal cord MRI was suggestive of transverse myelitis (Figure 1). Methylprednisolone, 30 mg/kg/day was started. The cerebrospinal fluid showed 37.0 cells/mm<sup>3</sup> of white blood cell count, 49 mg/dl of glucose, and 50.7 mg/dl of protein. Ceftriaxone and vancomycin were started.

On further questioning, the subject stated that her finger was bitten by a cat about two weeks before the beginning of the symptoms. Serological tests were positive for *Bartonella henselae* (IgM 1:160 and IgG 1:512). The therapy regimen was changed to doxycycline 100 mg and rifampin 300 mg both twice a day.

After four weeks of treatment, her symptoms improved but she continued with a radicular pain and weakness grade 3 in both legs. A second MRI of the spinal cord showed resolution of the transverse myelitis. An electroneuromyography revealed decreased motor nerve conduction velocity, prolonged distal motor latency, absent F waves, conduction blocks, and temporal dispersion in both peroneal and posterior tibial nerves. A diagnosis of possible Guillain-Barré syndrome was done. Intravenous immunoglobulin (IVIg) 0.4 g/kg/day was started over 5 days. After the fourth day

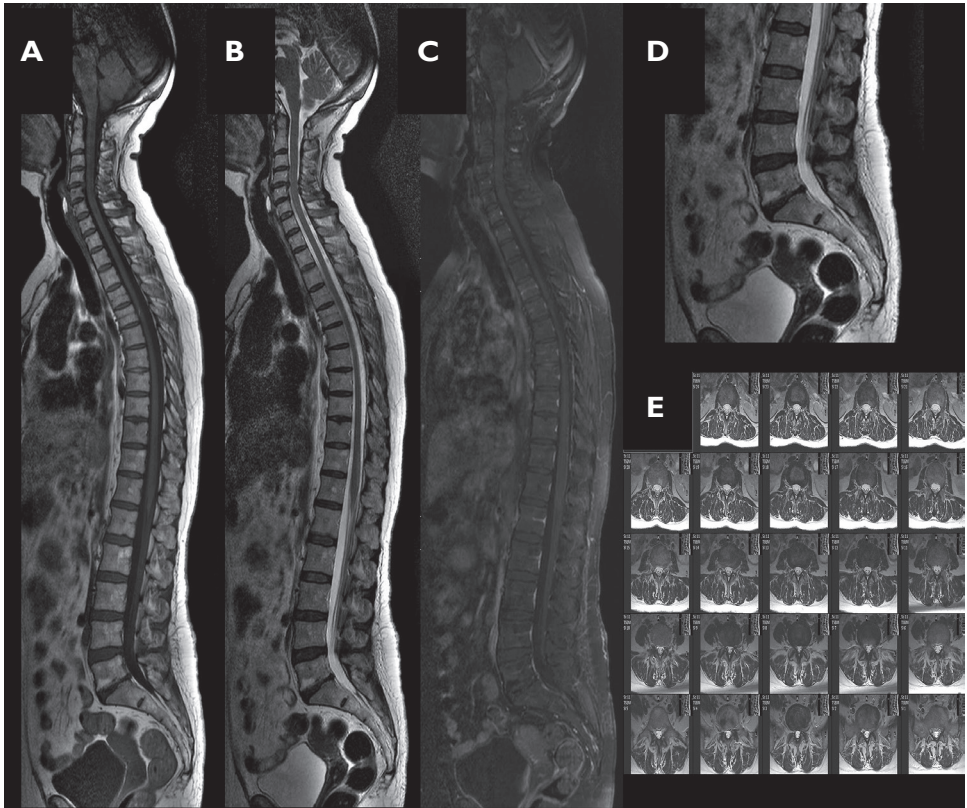


Figure 1 – Neuroimaging showing features of transverse myelitis, which is observed an area of T2-weighted hypersignal in the distal portion of the spinal cord. Sagittal T1-weighted (A), sagittal T2-weighted (B, E), sagittal T1-weighted SPIR (C), and axial T2-weighted magnetic resonance imaging.

of IVIG, the patient had recovery of her strength. Her neurological examination showed grade 4 in both legs. The patient was discharged, and the follow-up was lost.

### Discussion

Cat scratch disease (CSD) is caused by the proteobacterium *Bartonella henselae*. The most common type of transmission is by scratch/bite from an infected cat or direct contact with cat saliva into mucosal surfaces (Florin et al., 2008). This infectious disease is typically self-limited and characterized by mild febrile illness with regional lymphadenopathy. However, it can affect the visceral organ, neurologic, and ocular structures. In this context, the study of Salgado and Weisse (2000) demonstrated that three percent of neurological involvement in patients with CSD, and the most frequent manifestation was encephalopathy. GBS and ATM have been related simultaneously or consecutively with CSD (Carman et al., 2013; Mao and Hu, 2014).

**Table 1 – Case reports of patients with CSD who probably developed GBS/ATM overlap**

References		Carman et al. (2013)	Zakhour et al. (2018)	Present case
Age(years)/sex		12/M	10/F	62/F
Clinical symptoms at presentation		fever, back and leg pain, anuria, and inferior limb weakness	abdominal pain, vomiting, and urinary retention	fever, back pain, inferior limb weakness, and anuria
Comorbidities and medications in use		NR	none	dyslipidemia, simvastatin
Diagnosis Sequence	1 <sup>st</sup>	GBS	ATM	ATM
	2 <sup>nd</sup>	ATM	CSD	CSD
	3 <sup>rd</sup>	CSD	GBS	GBS
CSF analysis	protein (mg/dl)	1.9	55	50
	WBC (cells/mm <sup>3</sup> )	–	58	37
	glucose (mg/dl)	52	46	49
CSD	animal	cat	cat	cat
	time since the bite until admission (days)	10	7	15
	lymphadenopathy	bilateral cervical	left cervical	bilateral cervical, and axillary
	serological tests	IgG 1:320, IgM 0	IgG 1:152, IgM 1:160	IgG 1:320, IgM 1:160
	clinical symptoms	hyporeflexia	hyporeflexia	hyporeflexia and areflexia
GBS	EMG	demyelinating	mixed	demyelinating
	clinical symptoms	urinary retention, labile blood pressure	urinary retention	urinary retention, labile blood pressure
ATM	T2-weighted site	hyperintense T10–T12	hyperintense long	hyperintense T12-below
	contrast enhancement	yes	NR	yes
	edema	mild	NR	mild
	brain MRI	normal	abnormal, increased T2 signal in the left posterior periventricular and deep white matter	normal

	1 <sup>st</sup>	IVIG	ceftriaxone and vancomycin	methyl-prednisolone
Management sequence	2 <sup>nd</sup>	methyl-prednisolone	rifampin and doxycycline	ceftriaxone and vancomycin, rifampin and doxycycline
	3 <sup>rd</sup>	rifampicin, doxycycline	IVIG	IVIG
Follow-up		1 month later, hyporeflexia, able to walk without assistance, normal spinal MRI	4 months later, only residual sensory deficits	–

ATM – acute transverse myelitis; CSD – cat scratch disease; EMG – electroneuromyography; F – female; GBS – Guillain-Barré syndrome; IVIG – intravenous immunoglobulin; M – male; MRI – magnetic resonance imaging; NR – not reported

Guillain-Barré syndrome (GBS) is an eponym for a group of polyneuropathies that are acquired, acute, and immune-mediated. The most common form is the acute inflammatory demyelinating polyradiculoneuropathy, which accounts for at least 85% of the cases, and it is characterized by symmetrical ascending weakness associated with hyporeflexia/areflexia (Cosi and Versino, 2006). In this way, acute transverse myelitis (ATM) is a spinal cord syndrome with a relatively rapid onset of motor, sensory, and autonomic findings. It is usually attributed to a demyelinating lesion following an infection or as a continuum of inflammatory disorders such as multiple sclerosis (Berman et al., 1981). The superposition of the acquired peripheral neuropathy (GBS) and the central nervous system myelitis (ATM) is a syndrome possible undiagnosed and is known as GBS/ATM overlap (Mao and Hu, 2014). Thus, overlap syndromes are defined as the association of two conditions in a single subject.

Only a few cases of patients with CSD who develop GBS/ATM overlap have been reported in the literature. We identified two cases after a thorough review of the English-language published literature and we compared them with the present case (Table 1) (Carman et al., 2013; Zakhour et al., 2018). To the authors' knowledge, these cases describe pediatric individuals. Thus, the present is the first to report the CSD-GBS/ATM in an adult individual. A literature search was performed in Embase, Google Scholar, Lilacs, Medline, Scielo, and ScienceDirect, using a set of terms that included cat scratch disease, *Bartonella henselae*, Guillain-Barré syndrome, and acute transverse myelitis.

In the cases of Table 1, the individuals had good outcomes with only residual symptoms. This could be supported by some clinical features such as the electrophysiologic findings and respiratory symptoms. The studies of Mao and Hu

(2014), and Guo and Zhang (2019) showed that patients with better outcome have demyelinating findings on electrodiagnostic studies and do not need respiratory support throughout their hospitalization. It is worthy to note that sex, age, and the length of spinal cord lesions were not significantly associated with poor outcome in their study (Guo and Zhang, 2019). Therefore, the subjects of Table 1 are according to the published literature data.

GBS and ATM are considered neurological autoimmune disorders. Our hypothesis to explain the pathophysiology of CSD associated with the GBS/ATM overlap is based on molecular mimicry. There are approximately thirty studies in the literature about the GBS/ATM overlap, so probably a relationship among the pathogens already described and this overlap can be suspected (Guo and Zhang, 2019). In the study of Mao and Hu (2014), they state that maybe the overlap GBS/ATM may share more common etiologies and genetic backgrounds when compared with the other overlaps like the GBS and optic neuritis. In this way, probably the antecedent infection by the *Bartonella henselae* triggered the immune system to attack components of the peripheral (PNS) and central nervous system (CNS) through molecular mimicry. Many studies have been unsuccessful in the attempt of explaining the mechanism of GBS/ATM through the hypothesis that a pathogen elicits a common cascade of events responsible by the occurrence of both diseases (McDonald and Sadowsky, 2002; Mao and Hu, 2014; Guo and Zhang, 2019). Thus, it is possible that in rare cases the same pathogen provokes two separate processes simultaneously, which could result in two different diseases.

## Conclusion

In conclusion, a thorough patient's history should be obtained, and clinicians should be vigilant with the possible GBS/ATM overlap. In this way, it is essential to check the patient signs and symptoms throughout their hospitalization. We agree with the statement of Guo and Zhang (2019) that the GBS/ATM overlap is often undiagnosed.

## References

- Berman, M., Feldman, S., Alter, M., Zilber, N., Kahana, E. (1981) Acute transverse myelitis: incidence and etiologic considerations. *Neurology* **31**, 966–966.
- Carman, K. B., Yimenicioglu, S., Ekici, A., Yakut, A., Dinleyici, E. C. (2013) Co-existence of acute transverse myelitis and Guillain-Barré syndrome associated with *Bartonella henselae* infection. *Paediatr. Int. Child Health* **33**, 190–192.
- Cosi, V., Versino, M. (2006) Guillain-Barré syndrome. *Neurol. Sci.* **27**, s47–s51.
- Florin, T. A., Zaoutis, T. E., Zaoutis, L. B. (2008) Beyond cat scratch disease: Widening spectrum of *Bartonella henselae* infection. *Pediatrics* **121**, e1413–e1425.
- Guo, F., Zhang, Y. B. (2019) Clinical features and prognosis of patients with Guillain-Barré and acute transverse myelitis overlap syndrome. *Clin. Neurol. Neurosurg.* **181**, 127–132.
- Mao, Z., Hu, X. (2014) Clinical characteristics and outcomes of patients with Guillain-Barré and acquired CNS demyelinating overlap syndrome: a cohort study based on a literature review. *Neurol. Res.* **36**, 1106–1113.



- McDonald, J. W., Sadowsky, C. (2002) Spinal-cord injury. *Lancet* **359**, 417–425.
- Salgado, C. D., Weisse, M. E. (2000) Transverse myelitis associated with probable cat-scratch disease in a previously healthy pediatric patient. *Clin. Infect. Dis.* **31**, 609–611.
- Zakhour, R., Mancias, P., Heresi, G., Pérez, N. (2018) Transverse myelitis and Guillain-Barré syndrome associated with cat-scratch disease, Texas, USA, 2011. *Emerg. Infect. Dis.* **24**, 1754.

# A Single Small Bowel Hemangioma Detected by Video Capsule Endoscopy in a Patient Presenting with Iron-deficiency Anemia – Two Case Reports

**Dora Grgić<sup>1</sup>, Radovan Prijčić<sup>1</sup>, Ivan Romić<sup>2</sup>, Goran Augustin<sup>2</sup>,  
Pave Markoš<sup>1</sup>, Lea Korša<sup>3</sup>, Zlatko Marušić<sup>3</sup>, Nadan Rustemović<sup>1</sup>,  
Željko Krznarić<sup>1</sup>**

<sup>1</sup>Division of Gastroenterology and Hepatology, Department of Internal Medicine, University Hospital Centre Zagreb, Zagreb, Croatia;

<sup>2</sup>Department of Surgery, University Hospital Centre Zagreb, Zagreb, Croatia;

<sup>3</sup>Department of Pathology, University Hospital Centre Zagreb, Zagreb, Croatia

Received October 27, 2019; Accepted December 1, 2019.

**Key words:** Anemia – Small intestine – Capsule endoscopy – Occult blood – Vascular malformation

**Abstract:** Hemangioma of the small intestine is a rare vascular malformation which mostly presents as occult gastrointestinal bleeding and iron-deficiency anemia. Patients are often asymptomatic except of fatigue due to anemia. Hemangiomas can arise anywhere in the luminal gastrointestinal tract, with jejunum as the most commonly involved site. They are very hard to recognize mostly due to their localization. Video capsule endoscopy and balloon-assisted enteroscopy have very much improved preoperative diagnostics and made major contribution to establishing the diagnosis – which was very difficult in the past and almost all cases were diagnosed during or after the operation. Surgical resection is still the conventional treatment modality, although with the improvement of endoscopic therapeutic interventions (endoscopic mucosal resection, argon-plasma coagulation) there are more therapeutic possibilities.

**Mailing Address:** Dora Grgić, MD., Division of Gastroenterology and Hepatology, Department of Internal Medicine, University Hospital Centre Zagreb, Kispaticeva 12, Zagreb, Croatia; e-mail: dora.grgic1@gmail.com

## Introduction

We present two rare cases of an adult male patients presenting with iron-deficiency anemia for longer period of time and in whom after extensive work-up single small bowel hemangioma was found on video capsule endoscopy.

## Case report 1

We present a case of a 73-years-old male patient with evident iron-deficiency anemia, which was known for several years. Patient did not have black stools, he had no symptoms of fatigue, and no hematemesis, hematochezia, abdominal pain or fever. He had not lost any weight through that period of time. He was cardiac patient (PCI LAD years before) with known arterial hypertension, with antihypertensive therapy, anti-aggregation therapy and proton pump inhibitor for his chronic medical therapy. Also, he was taking iron oral supplements during past few years. In his family his father was diagnosed with gastric cancer. Our patient had several gastroscopies done in past few years – except *Helicobacter pylori* positive gastritis that was eradicated he had no other pathological findings.

Through day hospital comprehensive gastrointestinal workup was done: laboratory findings showed mild sideropenic, microcytic anemia, and results were negative upper and lower endoscopy and unsuspecting MR (magnetic resonance) enterography. Abdominal MSCT (multi-slice computed tomography) showed hypervascularization in one of the small bowel loops and tumour was suspected. The patient was referred for small-bowel video capsule endoscopy.

Small-bowel video capsule endoscopy revealed bluish mucosal discoloration in terminal ileum which was very unusual. We performed retrograde single-balloon enteroscopy and found suspicious bluish vascular tumour-like structure 60 cm

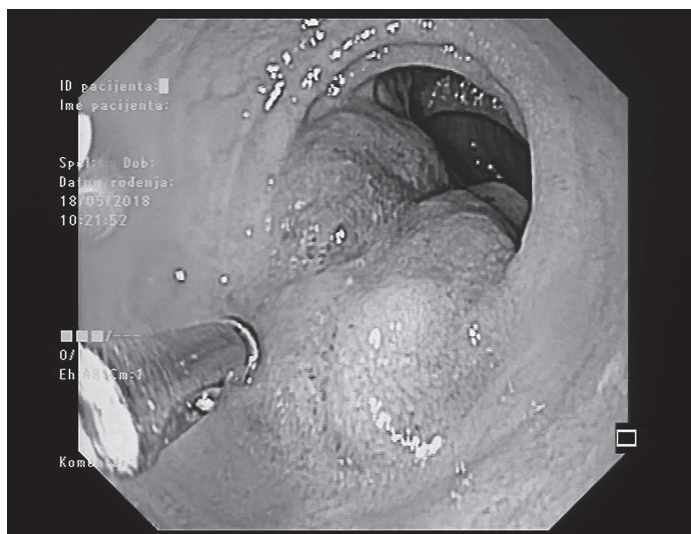


Figure 1 – Retrograde enteroscopy – tumour before taking biopsies.

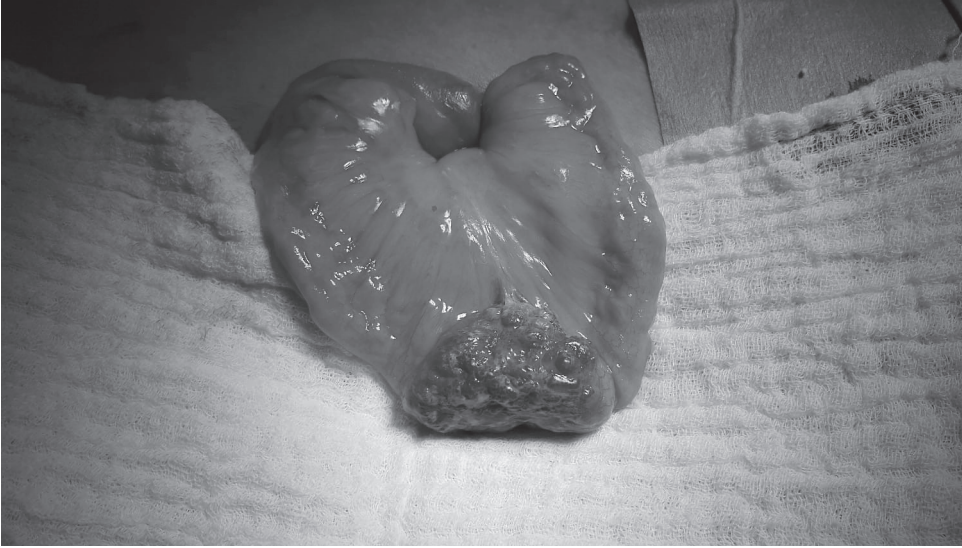

Figure 2 – Loop of small intestine with tumour.

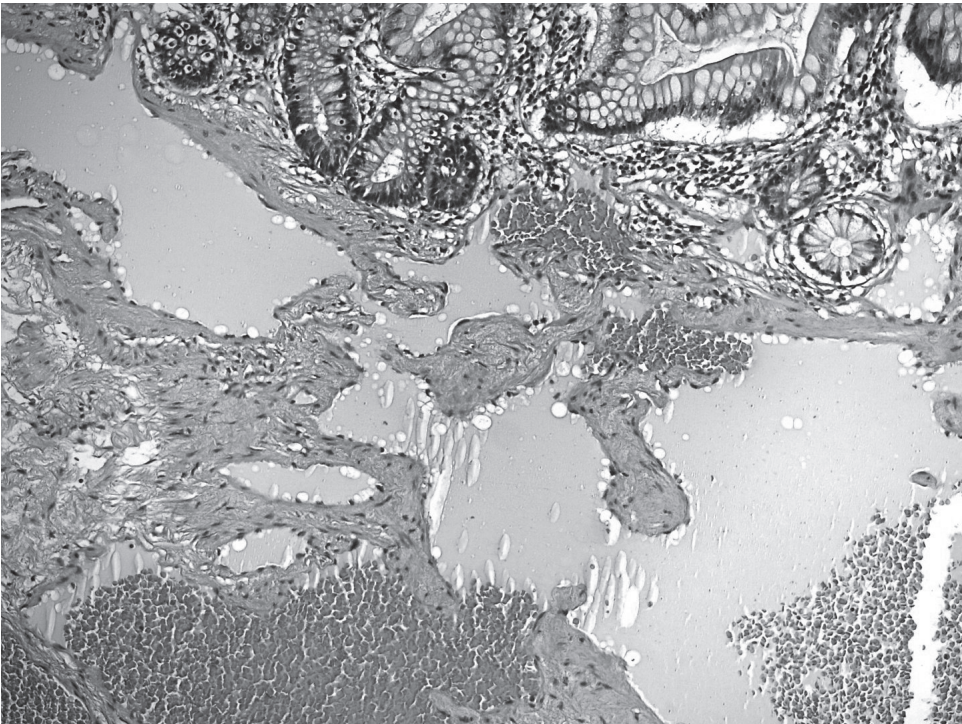


Figure 3 – Dilated tumoural blood vessels filled with erythrocytes, lined by a layer of bland endothelial cells (hematoxylin and eosin, 100×).

proximal of ileocecal (Bauchini) valve (Figure 1). Pathohistological specimens were negative for tumour cells and exploratory laparoscopy was scheduled.

During the surgery a single ileal tumour was resected (Figure 2) and histologic report confirmed intestinal hemangioma 2×2 cm in size (Figure 3).

After surgery patient recovered quickly and his haemoglobin levels in time of months increased to normal and remained stable during first year of follow-up.

## Case report 2

Male patient, 63-years-old, was admitted to hospital because of microcytic anemia which was recognized several months ago. He is only taking antihypertensive therapy, and his family history is negative for gastrointestinal or other tumours.

His main symptoms were constant fatigue and weakness in everyday normal life. His colonoscopy and gastroscopy were normal, without any pathology, and because of sideropenia he received parenteral iron in 2 occasions. Because of positive test for occult bleeding video capsule endoscopy was performed and it revealed polypoid bleeding lesion in distal third of jejunum and oral third of ileum. As anatomically this area of small intestine cannot be reached with enteroscope patient was scheduled

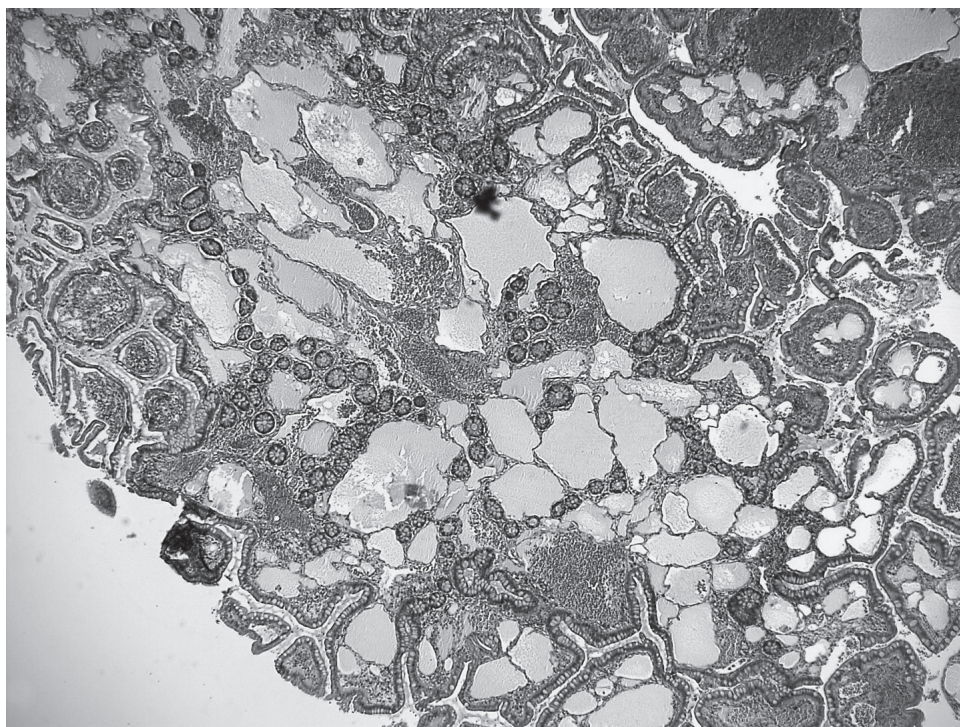


Figure 4 – A tumour composed of numerous thin-walled vessels located within the small intestinal submucosa (hematoxylin and eosin, 25×).

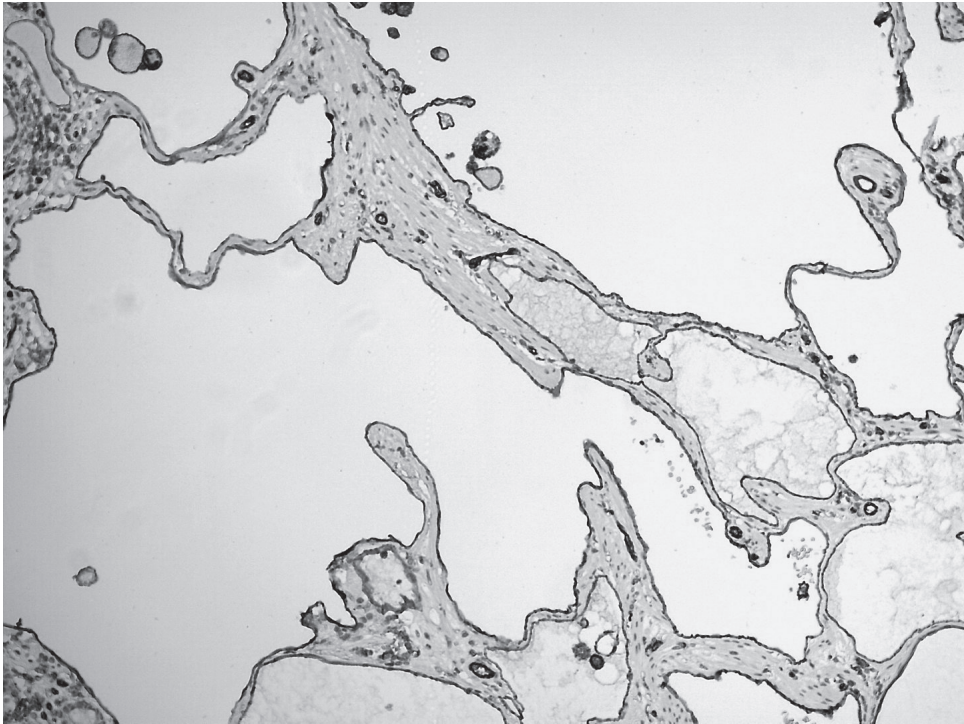


Figure 5 – Endothelial cells highlighted by the CD31 immunohistochemical stain (CD31, 100×).

for surgery. Laparoscopic exploration was performed, and surgeons found 8 cm long tumour between jejunum and ileum. Tumour was resected with LL enteroenteral anastomosis.

Pathohistological diagnosis was hemangioma (Figures 4 and 5).

This patient also recovered quickly after the surgery with normalisation of his hemoglobin and iron levels, with no more symptoms of fatigue and weakness.

## Discussion

We present two rare cases of solitary small bowel hemangioma causing iron-deficiency anemia in two adult male patients. Small bowel hemangiomas are rare and account for 7–10% of all benign neoplasms of the small intestine (Takase et al., 2017; Otani et al., 2018). Most patients present with abdominal pain and intestinal bleeding with iron-deficiency anemia. Rarely patients can present with intussusception, obstruction or perforation. Tumours can be solitary and multiple as a part of the blue rubber-bleb syndrome, Maffucci syndrome and Klippel-Trenaunay syndrome. Its size may range from a few millimetres to several centimetres. Video capsule endoscopy has revolutionized the diagnostic approach to obscure gastrointestinal

bleeding (Quentin et al., 2007; Pinho et al., 2008). It is a noninvasive imaging test which can be recommended when the source of bleeding remains unidentified after upper and lower endoscopy. In our case VCE (video capsule endoscopy) found suspicious lesion of the small intestine in two patients with long standing anemia. Enteroscopy which is invasive procedure can be both diagnostic and therapeutic tool. In our case it demonstrated suspicious finding in the small bowel (Durer et al., 2018). Surgical laparoscopy with intestinal resection established the final histologic diagnosis and in the same time allowing definitive, curative treatment. Endoscopic interventions such as endoscopic mucosal resection (EMR), endoscopic sclerotherapy and argon-plasma coagulation (APC) are possible therapeutic options, but they might result in uncontrolled bleeding or perforation since intestinal hemangiomas originate from the submucosal layer and some of them are transmural. So endoscopic interventions are preferred when multiple and/or small hemangiomas are present.

We present these two cases to motivate colleagues gastroenterologist/endoscopist and surgeons to think of and recognize this rare condition. It is also important to consider carefully indications for possible endoscopic treatment.

## References

- Durer, C., Durer, S., Sharbatji, M., Comba, I. Y., Aharoni, I., Majeer, U. (2018) Cavernous hemangioma of the small bowel: a case report and literature review. *Cureus* **10(8)**, e3113.
- Otani, K., Watanabi, T., Shimada, S., Hosomi, S., Nagami, Y., Tanaka, F., Kamata, N., Taira, K., Yamagami, H., Tanigawa, T., Shiba, M., Fujiwara, Y. (2018) Clinical utility of capsule endoscopy and double-balloon enteroscopy in the management of obscure gastrointestinal bleeding. *Digestion* **97**, 52–58.
- Pinho, R., Rodrigues, A., Proença, L., Silva, A. P., Fernandes, S., Leite, S., Amaral, I., De Sousa, P., Fraga, J. (2008) Solitary hemangioma of the small bowel disclosed by wireless capsule endoscopy. *Gastroenterol. Clin. Biol.* **32(1 Pt. 1)**, 15–18.
- Quentin, V., Lermite, E., Lebigot, J., Marinnes, M. Z., Arnaud, J. P., Boyer, J. (2007) Small bowel cavernous hemangioma: Wireless capsule endoscopy diagnosis of a surgical case. *Gastrointest. Endosc.* **65(3)**, 550–552.
- Takase, N., Fukui, K., Tani, T., Nishimura, T., Tanaka, T., Harada, N., Ueno, K., Takamatsu, M., Nishizawa, A., Okamura, A., Kaneda, K. (2017) Preoperative detection and localization of small bowel hemangioma: Two cases of small bowel hemangioma. *World J. Gastroenterol.* **23(20)**, 3752–3757.

# Gossypiboma: A Dramatic Result of Human Error, Case Report and Literature Review

**Yusuf Arikan, Osman Ozdemir, Kamil Gokhan Seker, Mithat Eksi, Ekrem Guner, Nadir Kalfazade, Selcuk Sahin, Ali Ihsan Tasci**

Department of Urology, Bakirkoy Dr. Sadi Konuk Training and Research Hospital, Istanbul, Turkey

Received April 14, 2019; Accepted December 1, 2019.

**Key words:** Gossypiboma – Foreign body – Renal cell carcinoma – Bladder cancer

**Abstract:** Gossypiboma refers to a retained foreign object that was forgotten in the body cavity during an operation. It is a rare surgical complication that most commonly occurs after intraperitoneal abdominal emergency surgical procedures, but may also occur after virtually any type of operation. Gossypiboma can be confused with neoplastic lesions and abscess. Clinical examination and radiological findings may sometimes mislead the physician. We intend to present our cases, which is thought to be a kidney tumour and bladder cancer but resulted gossypiboma which is a condition that is caused by a forgotten sponge during the operation and it can mimic the cancer. During the operation, the team must work in coordination and be careful. Unnecessary operations in such situation can significantly increase the patient's morbidity.

**Mailing Address:** Yusuf Arikan, MD., Department of Urology, Bakirkoy Dr. Sadi Konuk Training and Research Hospital, Tevfik Saglam Caddesi No. 11 Zuhuratbaba/Bakirkoy, Istanbul 34147, Turkey; Phone: +900 542 204 93 28; e-mail: dryusufarikan@gmail.com



## Introduction

Gossypiboma is a rare situation caused by the forgetting a surgical sponge in the body cavities during a surgical operation and consequently by the reaction of the body to foreign matter. The term “gossypiboma” is derived from the Latin gossypium (cotton wool, cotton) and the suffix -oma, meaning a tumour or growth, and describes a mass within a patient’s body comprising a cotton matrix surrounded by a foreign body granuloma (Alayo et al., 2010).

Although gossypiboma is a lesion that can mimic benign or malignant tumours or abscess, its diagnosis can usually be done years after the surgery. On the other hand, it is rarely reported for medicolegal reasons (Manzella et al., 2009).

“Emergency operation” and “poor communication” were stated as the risk factors of forgetting a surgical sponge, which is the cause of the gossypiboma (Wan et al., 2009).

Patients may present with nonspecific symptoms that are the result of a foreign body related inflammatory process, or they may be asymptomatic and be diagnosed incidentally (Dakubo et al., 2009).

## Case report

### Case 1

During routine controls of a 74-year-old man, an approximately 5×5 cm in diameter mass lesion was detected in the middle pole of the left kidney. The patient’s comorbidities included hypertension (HT), polycystic kidney disease and chronic renal failure (CRF). He had a history of left open pyelolithotomy and cholecystectomy 20 years ago. MRI (magnetic resonance imaging) showed a 5.5×4.5 cm in diameter smooth contoured contrast enhanced lesion with an exophytic extension in the mid-lower section of the left kidney (Figure 1). Left

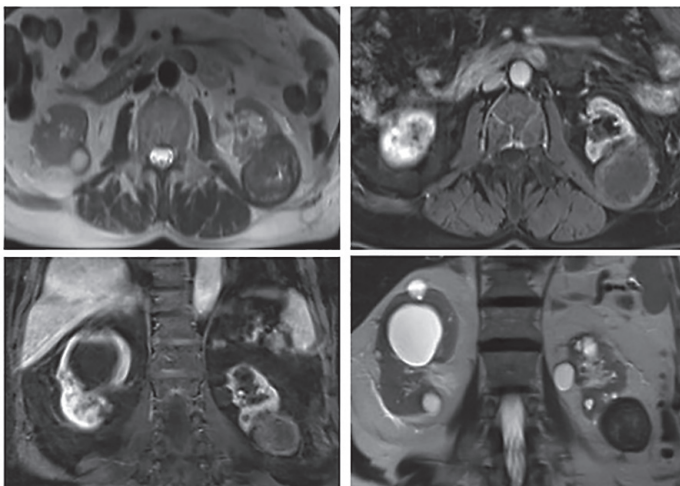


Figure 1 – A contrast-enhanced magnetic resonance imaging scan of lesion in the posterior pole of the left kidney.

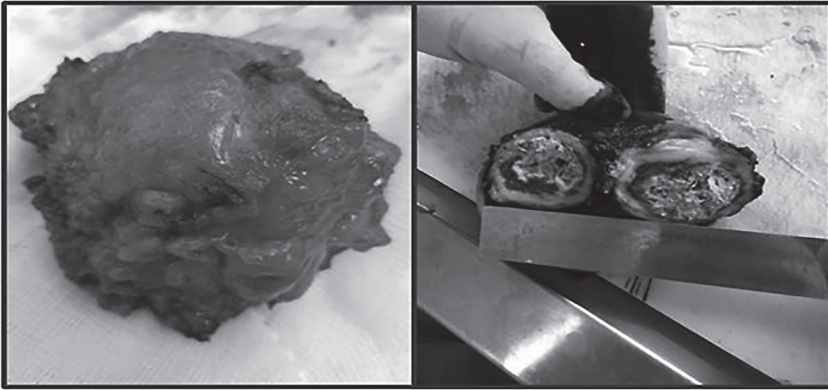


Figure 2 – The macroscopic images of pathological specimen.

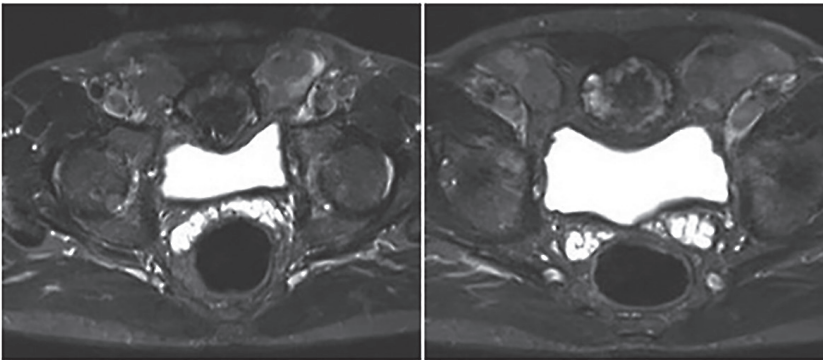


Figure 3 – A contrast-enhanced computed tomography scan of the lesion in the bladder anterior wall that induced to bladder.

partial nephrectomy was performed in the patient with suspicious appearance for malignancy. The macroscopic pathological specimen is shown in Figure 2. Microscopic examination of partial nephrectomy material showed fibrinous material in the cytoplasm of histiocytes, some of which are multinucleated. The pathology report resulted as foreign body type chronic inflammatory granulation tissue. It was thought that was a result of forgotten surgical sponge in the operation area due to open left pyelolithotomy 20 years ago.

#### Case 2

A 52-year-old woman presented with dysuria and frequent urination. The patient had no chronic disease. She had a history of open cystolithotomy six years ago. Imaging showed a 45×42 mm in diameter heterogeneous contrast enhanced mass lesion in mesentery tissue in the bladder dome (Figure 3). Cystoscopic examination showed protruding and encrusted threads that might be a part of impacted surgical

gauze at the dome of the bladder. Pelvic exploration and foreign body removal were performed. Pathology results were reported as active chronic inflammation with foreign body type giant cells. It was thought that the patient was presented in this way due to the gauze that had been forgotten during an open cystolithotomy operation 6 years ago.

## Discussion

Gossypiboma is not accurately reported for medico-legal reasons and its actual incidence is difficult to predict. However, there are publications indicating that the frequency is 1 in 4,000 (Kiernan et al., 2008). In another publication, it was reported that the ratio ranged from 1 in 1,000 and 1 in 300 cases in all surgical cases, and between 1 in 1,500 and 1 in 1,000 cases in intraabdominal cases (Lincourt et al., 2007).

Complaints of patients with gossypiboma depend on the inflammatory process of the body against foreign bodies (Dakubo et al., 2009). There are different responses in the early and late periods, depending on the forgotten material. In the early period, problems such as abscesses and infections occur, but in the late period, problems such as obstruction and chronic pain due to adhesions are encountered (Sakorafas et al., 2010). Gomes et al. (2017) described gossypiboma as a life-threatening surgical site infection and stated that this might be a cause of sepsis.

The patients can be completely asymptomatic and may be diagnosed incidentally, but gossypiboma may also appear with complaints similar to intestinal obstruction, intestinal fistula, malabsorption syndrome or diffuse peritonitis (Iglesias and Salomao, 2007). It's been stated that gossypiboma is a lesion that can mimic benign or malignant tumours and abscess (Manzella et al., 2009). In one of the cases we presented, the patient was completely asymptomatic and underwent surgery with a preliminary diagnosis of renal tumour. In the other case, the patient presented with lower urinary tract symptoms and was diagnosed with cystoscopy.

Parashari et al. (2012) stated that gauze forgetting is an important and preventable cause of morbidity. In a review of 254 patients published by Wan et al. (2009), it was concluded that the most important predisposing factors of gauze forgetting are "emergency operation" and "poor communication". When we look at these studies, gossypiboma is a widely preventable condition in the literature and is the result of an absolute human error.

Gossypiboma is not a frequently diagnosed lesion and requires clinician's suspicion (Apter et al., 1990). In patients with long-standing nonspecific symptoms, the history of the patient should also be questioned and especially if there is a history of previous surgery, gossypiboma should be considered (Karasaki et al., 2013; Rehman et al., 2014).

Gossypiboma appears as a spongy structure with characteristic gas bubbles in radiological examinations. Calcification and contrast enhancement may also occur in the lesion wall (O'Connor et al., 2003).

In the medicolegal aspect, gossypiboma is a medical negligence and it can be avoidable. In the surgeon's side it can cause humiliation, mental suffering or maybe charges for malpractice. In the patients side it may cause increased morbidity or mortality and this situation can cause medical and legal problems between surgeon and patients (Biswas et al., 2012).

The final treatment of gossypiboma is described as surgical operation and removal of foreign body. Today, the gauze count is shown as the gold standard to prevent gossypiboma and to avoid from gauze forgetting (Rehman et al., 2017).

## Conclusion

Gossypiboma is an unpleasant condition that occurs due to a forgotten foreign body in the body during operation. It sometimes causes no symptoms at all, and in some cases mimics the tumour, may cause indeterminate pain in patients, and may be the cause of sepsis and cause of death.

When the diagnosis of gossypiboma is made, the absolute solution is the removal of the foreign body with surgery and the gauze must be counted in every operation to prevent gossypiboma. The best approach to prevent such problems requires the operation team to have appropriate communication with each other to avoid situations that cause inattention.

## References

- Alayo, E., Attar, B., Go, B. (2010) A case of recurrent abdominal pain due to a gossypiboma with spontaneous resolution. *Clin. Gastroenterol. Hepatol.* **8**, e13–e14.
- Apter, S., Hertz, M., Rubinstein, Z. J., Zissin, R. (1990) Gossypiboma in the early post-operative period: a diagnostic problem. *Clin. Radiol.* **42**, 128–129.
- Biswas, R. S., Ganguly, S., Saha, M. L., Saha, S., Mukherjee, S., Ayaz, A. (2012) Gossypiboma and surgeon – Current medicolegal aspect – a review. *Indian J. Surg.* **74(4)**, 318–322.
- Dakubo, J., Clegg-Lampsey, J., Hodasi, W., Obaka, H., Toboh, H., Asempa, W. (2009) An intra-abdominal gossypiboma. *Ghana Med. J.* **43(1)**, 43–45.
- Gomes, C. A., Catena, F., Soares, C. Jr., Sartelli, M., di Saverio, S., Gomes, F. C., Gomes, C. C. (2017) Septic abdominal gossypiboma: A life threatening surgical site infection. *JoPER* **2**, 70.
- Iglesias, A. C., Salomao, R. M. (2007) Gossypiboma intra-abdominal – Análise de 15 casos. *Rev. Col. Bras. Cir.* **34**, 106–113. (in Portuguese)
- Karasaki, T., Nomura, Y., Nakagawa, T., Tanaka, N. (2013) Beware of gossypibomas. *BMJ Case Rep.* **2013**.
- Kiernan, F., Joyce, M., Byrnes, C. K., O'Grady, H., Keane, F. B., Neary, P. (2008) Gossypiboma: A case report and review of the literature. *Ir. J. Med. Sci.* **177**, 389–391.
- Lincourt, A. E., Harrell, A., Cristiano, J., Sechrist, C., Kercher, K., Heniford, B. T. (2007) Retained foreign bodies after surgery. *J. Surg. Res.* **138**, 170–174.
- Manzella, A., Filho, P. B., Albuquerque, E., Farias, F., Kaercher, J. (2009) Imaging of gossypibomas: pictorial review. *AJR Am. J. Roentgenol.* **193**, S94–S101 (Suppl. 6).
- O'Connor, A. R., Coakley, F. V., Meng, M. V., Eberhardt, S. (2003) Imaging of retained surgical sponges in the abdomen and pelvis. *AJR Am. J. Roentgenol.* **180**, 481–489.
- Parashari, U. C., Khanduri, S., Saxena, S., Bhadury, S. (2012) Gossypiboma: An important preventable cause of morbidity. *Ann. Trop. Med. Public Health* **5**, 397–399.

- Rehman, A., Baloch, N. U., Awais, M. (2014) Gossypiboma diagnosed fifteen years after a cesarean section: a case report. *Qatar Med. J.* **2014**, 65–69.
- Rehman, A., Ul-Ain Baloch, N., Awais, M. (2017) Gossypiboma (retained surgical sponge): an evidence-based review. *Open J. Surg.* **1(1)**, 8–14.
- Sakorafas, G. H., Sampanis, D., Lappas, C., Papantoni, E., Christodoulou, S., Mastoraki, A., Safioleas, M. (2010) Retained surgical sponges: What the practicing clinician should know. *Langenbecks Arch. Surg.* **395**, 1001–1007.
- Wan, W., Le, T., Riskin, L., Macario, A. (2009) Improving safety in the operating room: A systematic literature review of retained surgical sponges. *Curr. Opin. Anaesthesiol.* **22**, 207–214.

## Instructions to Authors

Prague Medical Report is an English multidisciplinary biomedical journal published quarterly by the First Faculty of Medicine of the Charles University. Prague Medical Report (Prague Med Rep) is indexed and abstracted by Index-medicus, MEDLINE, PubMed, CNKI, DOAJ, EBSCO, and Scopus.

### Articles issued in the journal

- a) Primary scientific studies on the medical topics (not exceeding 30 pages in standardized A4 format – i.e. 30 lines and 60–65 characters per line – including tables, graphs or illustrations)
- b) Short communications
- c) Case reports
- d) Reviews
- e) Lectures or discourses of great interest
- f) Information about activities of the First Faculty of Medicine and other associated medical or biological organizations

### Layout of the manuscript

- a) Title of the study (brief and concise, without abbreviations)
- b) Information about the author(s) in the following form:
  - first name and surname of the author(s) (without scientific titles)
  - institution(s) represented by the author(s)
  - full corresponding (mailing) author's reference address (including first name, surname and scientific titles, postal code, phone/fax number and e-mail)
- c) Abstract (maximum 250 words)
- d) Key words (4–6 terms)
- e) Running title (reduced title of the article that will appear at the footer (page break), not more than 50 typewritten characters including spaces)
- f) Introduction
  - The use of abbreviations should be restricted to SI symbols and those recommended by the IUPAC-IUB. Abbreviations should be defined in brackets on first appearance in the text. Standard units of measurements and chemical symbols of elements may be used without definition.
- g) Material and Methods
- h) Results
- i) Discussion

## j) Conclusion

## k) References

- All the sources of relevant information for the study should be cited in the text (citations such as “personal communication” or “confidential data” are not accepted).
  - It is not permitted to cite any abstract in the References list.
  - References should be listed alphabetically at the end of the paper and typed double-spaced on separate pages. First and last page numbers must be given. Journal names should be abbreviated according to the Chemical Abstract Service Source Index. All co-authors should be listed in each reference (et al. cannot be used).
  - Examples of the style to be used are:  
 Yokoyama, K., Gachelin, G. (1991) An Abnormal signal transduction pathway in CD4–CD8– double-negative lymph node cells of MRL *lpr/lpr* mice. *Eur. J. Immunol.* **21**, 2987–2992.  
 Loyd, D., Poole, R. K., Edwards, S. W. (1992) *The Cell Division Cycle. Temporal Organization and Control of Cellular Growth and Reproduction.* Academic Press, London.  
 Teich, N. (1984) Taxonomy of retroviruses. In: *RNA Tumor Viruses*, eds. Weiss, R., Teich, N., Varmus, H., Coffin, J., pp. 25–207, Cold Spring Harbor Laboratory, Cold Spring Harbor, New York.
- References in the text should be cited as follows: two authors, Smith and Brown (1984) or (Smith and Brown, 1984); three or more authors, Smith et al. (1984) or (Smith et al., 1984). Reference to papers by the same author(s) in the same year should be distinguished in the text and in the reference list by lower-case letters, e.g. 1980a, or 1980a, b.

## l) tables, figures, illustrations, graphs, diagrams, photographs, etc. (incl. legends)

**Technical instructions**

- a) Manuscripts (in UK English only) must be delivered in the electronic form via Online Manuscript Submission and Tracking system (<http://www.praguemedicalreport.org/>). In case of problems, contact the Prague Medical Report Office ([medical.report@lf1.cuni.cz](mailto:medical.report@lf1.cuni.cz)). The online submission has to include the complete version of the article in PDF format, separately the manuscript as a MS Word file and a cover letter. The detailed version of the Instructions to Authors can be found at: [http://www.praguemedicalreport.org/download/instructions\\_to\\_authors.pdf](http://www.praguemedicalreport.org/download/instructions_to_authors.pdf).
- b) Text should be written in MS WORD only. We accept only documents that have been spell-checked with UK English as a default language.
- c) Please, write your text in Times New Roman script, size 12, and line spacing 1.5.
- d) Text should be justified to the left, with no paragraph indent (use Enter key only); do not centre any headings or subheadings.

- e) Document must be paginated-numbered beginning with the title page.
- f) Tables and graphs should represent extra files, and must be paginated too.
- g) Edit tables in the following way: Make a plain text, indent by Tab (arrow key) all the data belonging to a line and finish the line by Enter key. For all the notes in table, use letter x, not \*.
- h) Make your graphs only in black-and-white. Deliver them in electronic form in TIFF or JPG format only.
- i) Deliver illustrations and pictures (in black-and-white) in TIFF or JPG format only. The coloured print is possible and paid after agreement with the Prague Medical Report Office.
- j) Mark all the pictures with numbers; corresponding legend(s) should be delivered in an extra file. Mark the position of every picture (photo) in the manuscript by the corresponding number; keep the order 1, 2, 3...

### **Authors' Declaration**

The corresponding (or first author) of the manuscript must print, fill and sign by his/her own hand the Authors Declaration and fax it (or send by post) to the Prague Medical Report Office. Manuscript without this Declaration cannot be published. The Authors' Declaration can be found by visiting our web pages: <http://pmr.lf1.cuni.cz> or web pages of Prague Medical Report Online Manuscript Submission and Tracking system: <http://www.praguemedicalreport.org/>.

### **Editorial procedure**

Each manuscript is evaluated by the editorial board and by a standard referee (at least two expert reviews are required). After the assessment the author is informed about the result. In the case the referee requires major revision of the manuscript, it will be sent back to the author to make the changes. The final version of the manuscript undergoes language revision and together with other manuscripts, it is processed for printing.

Concurrently, proofs are electronically sent (in PDF format) to the corresponding (mailing) author. Author is to make the proofs in PDF paper copy and deliver it back to the editorial office by fax or as a scanned file by e-mail. Everything should be done in the required time. Only corrections of serious errors, grammatical mistakes and misprints can be accepted. More extensive changes of the manuscript, inscriptions or overwriting cannot be accepted and will be disregarded. Proofs that are not delivered back in time cannot be accepted.

### **Article processing charge**

Authors do not pay any article processing charge.

### **Open Access Statement**

This is an open access journal which means that all content is freely available without charge to the user or his/her institution. Users are allowed to read, download, copy,



distribute, print, search, or link to the full texts of the articles, or use them for any other lawful purpose, without asking prior permission from the publisher or the author. This is in accordance with the BOAI definition of open access.

### **Copyright Statement**

The journal applies the Creative Commons Attribution 4.0 International License to articles and other works we publish. If you submit your paper for publication by Prague Medical Report, you agree to have the CC BY license applied to your work. The journal allows the author(s) to hold the copyright without restrictions.

Editorial Office

Prague Medical Report

Kateřinská 32, 121 08 Prague 2, Czech Republic

e-mail: [medical.report@lf1.cuni.cz](mailto:medical.report@lf1.cuni.cz)

Phone: +420 224 964 570. Fax: +420 224 964 574

# Annual Contents

## No. 1

### Primary Scientific Studies

Gastric pH in Rats: Key Determinant for Preclinical Evaluation of pH-dependent Oral Drug Absorption / Šíma M., Kutinová-Canová N., Ryšánek P., Hořínková J., Moškořová D., Slanař O. page 5

Is Cardiometabolic Index a Predictive Marker for Renal Cell Cancer Aggressiveness? / Dursun M., Besiroglu H., Otunctemur A., Ozbek E. page 10

### Case Reports

Immediate Removal of an Entrapped Central Venous Catheter Guide Wire / Bruthans J., Trča S. page 18

Primary Adrenal Squamous Cell Carcinoma in a Single Kidney Patient: Case Report and Review of Literature / Kardoust Parizi M. page 24

**Instructions to Authors** page 30

## No. 2–3

### Reviews

Lipoprotein(a) – Link between Atherogenesis and Thrombosis / Labudovic D., Kostovska I., Tosheska Trajkovska K., Cekovska S., Brezovska Kavrakova J., Topuzovska S. page 39

Pharmacokinetics of Dasatinib / Hořínková J., Šíma M., Slanař O. page 52

### Primary Scientific Studies

Evaluation of Complications Following a Trans-masseteric Antero-parotid Approach for Patients with Sub-condylar Fractures of Their Temporomandibular Joint. A Retrospective Study / Machoň V., Desai A., Levorová J., Hirjak D., Brizman E., Foltán R. page 64

The Role of Magnetic Resonance Spectroscopy Imaging Parameters to Predict Early Biochemical Recurrence after Radical Prostatectomy / *Kardoust Parizi M., Razi A., Alizadeh S., Kasaeian A.*

page 74

Sarcoporosis Is a Part of Aging / *Broulík P.*

page 84

### **Case Reports**

Cerebellar Squamous Cell Carcinoma Due to Malignant Transformation of Cerebellopontine Angle Epidermoid Cyst, Report an Interesting Case and Review the Literature / *Fereydonyan N., Taheri M., Kazemi F.*

page 95

Kinetics of Myristic Acid Following Accidentally Induced Septic Response / *Zazula R., Průcha M., Pehal F., Dryahina K., Moravec M., Müller M., Nejštek T.*

page 103

### **Instructions to Authors**

page 107

## **No. 4**

### **Primary Scientific Studies**

Immunolocalization of Gas7 in the Subgranular Zone of Mice Hippocampus / *Kumar U.*

page 117

### **Case Reports**

Attenuated Type of Asphyxiating Thoracic Dysplasia due to Mutations in *DYNC2H1* Gene / *Čechová A., Baxová A., Zeman J., Lambert L., Honzík T., Leiská A., Čunát V., Tesařová M.*

page 124

Transverse Myelitis and Guillain-Barré Syndrome Overlap Secondary to *Bartonella henselae*: Case Report / *Rissardo J. P., Caprara A. L. F.*

page 131

A Single Small Bowel Hemangioma Detected by Video Capsule Endoscopy in a Patient Presenting with Iron-deficiency Anemia – Two Case Reports / *Grgić D., Prijčić R., Romić I., Augustin G., Markoš P., Korša L., Marušić Z., Rustemović N., Krznarić Ž.*

page 138

Gossypiboma: A Dramatic Result of Human Error, Case Report and Literature Review / *Arıkan Y., Ozdemir O., Seker K. G., Eksi M., Guner E., Kalfazade N., Sahin S., Tasci A. I.*

page 144

### **Instructions to Authors**

page 150

### **Annual Contents**

page 154

### **Annual Nominal Index**

page 156

### **Annual Referee Index**

page 157

# Annual Nominal Index

ISSN 1214-6994

- Alizadeh S. 2-3/74-83  
Ankan Y. 4/144-149  
Augustin G. 4/138-143  
Baxová A. 4/124-130  
Besiroglu H. 1/10-17  
Brezovska Kavrakova J. 2-3/39-51  
Brizman E. 2-3/64-73  
Broulík P. 2-3/84-94  
Bruthans J. 1/18-23  
Caprara A. L. F. 4/131-137  
Čechová A. 4/124-130  
Cekovska S. 2-3/39-51  
Čunát V. 4/124-130  
Desai A. 2-3/64-73  
Dryahina K. 2-3/103-106  
Dursun M. 1/10-17  
Eksi M. 4/144-149  
Fereydonyan N. 2-3/95-102  
Foltán R. 2-3/64-73  
Grgić D. 4/138-143  
Guner E. 4/144-149  
Hirjak D. 2-3/64-73  
Honzík T. 4/124-130  
Hořinková J. 1/5-9; 2-3/52-63  
Kalfazade N. 4/144-149  
Kardoust Parizi M. 1/24-29; 2-3/74-83  
Kasaeian A. 2-3/74-83  
Kazemi F. 2-3/95-102  
Korša L. 4/138-143  
Kostovska I. 2-3/39-51  
Krznaric Ž. 4/138-143  
Kumar U. 4/117-123  
Kutinová-Canová N. 1/5-9  
Labudovic D. 2-3/39-51  
Lambert L. 4/124-130  
Leiská A. 4/124-130  
Levorová J. 2-3/64-73  
Machoň V. 2-3/64-73  
Markoš P. 4/138-143  
Marušić Z. 4/138-143  
Moravec M. 2-3/103-106  
Moškořová D. 1/5-9  
Müller M. 2-3/103-106  
Nejtek T. 2-3/103-106  
Otuntemur A. 1/10-17  
Ozbek E. 1/10-17  
Ozdemir O. 4/144-149  
Pehal F. 2-3/103-106  
Prijic R. 4/138-143  
Průcha M. 2-3/103-106  
Razi A. 2-3/74-83  
Rissardo J. P. 4/131-137  
Romić I. 4/138-143  
Rustemović N. 4/138-143  
Ryšánek P. 1/5-9  
Sahin S. 4/144-149  
Seker K. G. 4/144-149  
Šíma M. 1/5-9; 2-3/52-63  
Slanař O. 1/5-9; 2-3/52-63  
Taheri M. 2-3/95-102  
Tasci A. I. 4/144-149  
Tesařová M. 4/124-130  
Topuzovska S. 2-3/39-51  
Tosheska Trajkovska K. 2-3/39-51  
Trča S. 1/18-23  
Zazula R. 2-3/103-106  
Zeman J. 4/124-130

# Annual Referee Index

Prague Medical Report thanks to Reviewers, consulted in 2019:

**Antonín Brisuda, MD., PhD., FEBU,**

Department of Urology, Second Faculty of Medicine, Charles University and University Hospital Motol, Czech Republic; **(twice)**

**Mgr. Hana Brožka,** Institute of Physiology CAS, Prague, Czech Republic;

**Lenka Fialová, MD., PhD.,** Institute of Medical Biochemistry and Laboratory Diagnostics, First Faculty of Medicine, Charles University and General University Hospital in Prague, Czech Republic;

**Assoc. Prof. Jiří Heráček, MD., PhD., MBA,** Department of Urology, Military University Hospital Prague, Czech Republic;

**Ivan Herold, MD., PhD.,** District Hospital Mladá Boleslav, Mladá Boleslav, Czech Republic;

**MDDr. Jan Jambura, MD.,** Department of Stomatology, Faculty of Medicine in Plzeň, Charles University and University Hospital Plzeň, Czech Republic;

**Assoc. Prof. PharmDr. Jan Juřica, PhD.,** Department of Pharmacology, Faculty of Medicine, Masaryk University in Brno, Czech Republic;

**Filip Kramář, MD., PhD.,** Department of Neurosurgery and Neurooncology, First Faculty of Medicine, Charles University and Military University Hospital Prague, Czech Republic;

**Assoc. Prof. Ing. Lukáš Lambert, MD., PhD.,** Department of Radiology, First Faculty of Medicine, Charles University and General University Hospital in Prague, Czech Republic;

**Assoc. Prof. Jiří Málek, MD., PhD.,** Department of Anaesthesiology and

Resuscitation, Third Faculty of Medicine, Charles University and University Hospital Královské Vinohrady, Czech Republic;

**Assoc. Prof. Jan Martínek, MD., PhD.,** Institute of Clinical and Experimental Medicine, Prague, Czech Republic;

**Jaroslav Pacovský, MD., PhD.,** Department of Urology, Faculty of Medicine in Hradec Králové, Charles University and University Hospital Hradec Králové, Czech Republic;

**Renata Černá Pařízková, MD., PhD.,** Department of Anesthesiology, Resuscitation and Intensive Medicine, Faculty of Medicine in Hradec Králové, Charles University and University Hospital Hradec Králové, Czech Republic;

**Assoc. Prof. Dagmar Procházková, MD., PhD.,** Department of Pediatrics, Faculty of Medicine, Masaryk University in Brno and University Hospital Brno, Czech Republic;

**Prof. RNDr. Luboslav Stárka, MD., DSc.,** Institute of Endocrinology, Prague, Czech Republic;

**Assoc. Prof. PharmDr. Martin Štěřba, PhD.,** Department of Pharmacology, Faculty of Medicine in Hradec Králové, Charles University, Czech Republic;

**Petr Stránský, MD., PhD.,** Department of Urology, Faculty of Medicine in Plzeň, Charles University and University Hospital Plzeň, Czech Republic;

**Assoc. Prof. Martin Vališ, MD., PhD.,** Department of Neurology, Faculty of Medicine in Hradec Králové, Charles University and University Hospital Hradec Králové, Czech Republic;

**Assoc. Prof. RNDr. Anna Yamamotová, PhD.,** Department of Physiology, Third Faculty of Medicine, Charles University, Czech Republic;

**Prof. Zdeněk Zadák, MD., PhD.,** 3<sup>rd</sup> Department of Internal Medicine – Metabolic Care and Gerontology, Faculty of Medicine in Hradec Králové, Charles University and

University Hospital Hradec Králové, Czech Republic;

**Assoc. Prof. Roman Záhorec, MD., PhD.,** Oncological Institute of St. Elizabeth, Bratislava, Slovak Republic;

**Kateřina Zajíčková, MD., PhD.,** Institute of Endocrinology, Prague, Czech Republic



# Prague Medical REPORT

(Sborník lékařský)

Published by the First Faculty of Medicine, Charles University, Karolinum Press,  
Ovocný trh 560/5, 116 36 Praha 1 – Staré Město, Czech Republic, [www.karolinum.cz](http://www.karolinum.cz)

*Editorial Office:* Prague Medical Report, Kateřinská 32, 121 08 Prague 2, Czech Republic,  
Phone: +420 224 964 570, Fax: +420 224 964 574,

e-mail: [medical.report@lf1.cuni.cz](mailto:medical.report@lf1.cuni.cz)

*Editor in Chief:* Kateřina Jandová, MD., PhD.

*Editor:* Assoc. Prof. Jan Šváb, MD., PhD.

*Foreign Language Editor:* Prof. Jaroslav Pokorný, MD., DSc.

*Executive Editors:* Mgr. Jiří Frühauf, Mgr. Lucie Šulcová

*Editorial Board:* Prof. Jan Betka, MD., DSc.; Zdeněk Kostrouch, MD., PhD.;

Prof. Emanuel Nečas, MD., DSc.; Prof. František Perlík, MD., DSc.;

Prof. Karel Smetana, MD., DSc.; Prof. Karel Šonka, MD., DSc.;

Assoc. Prof. Jan Tošovský, MD., PhD.; Prof. Jiří Zeman, MD., DSc.

Published as quarterly journal. Typeset and printed by Karolinum Press.

Annual subscription (4 issues) EUR 60,–. Single copy EUR 20,–.

Distribution: Karolinum Press, Ovocný trh 560/5,

116 36 Praha 1, Czech Republic, e-mail: [journals@karolinum.cz](mailto:journals@karolinum.cz)

ISSN 1214-6994 (Print)

ISSN 2336-2936 (Online)

Reg. No. MK ČR E 796