

# Cervical Cystic Lymphangioma in an Adult Patient. A Case Report of a Rare Entity

---

Andrianos-Serafeim Tzortzis<sup>1</sup>, Vasileios P. Maniatakos<sup>2</sup>, Simeon Tsintzos<sup>2</sup>, George Tzortzis<sup>3,\*</sup>

## ABSTRACT

Cystic lymphangioma (CL) is a rare benign tumour that arises from the lymphatic vessels. The most common site of presentation is the posterior triangle of the neck. 90% of the lesions are diagnosed before the age of two years old and only a small number is reported in adults. In this paper, we describe the diagnostic and treatment approach of a cervical CL in an adult male.

## KEYWORDS

cystic lymphangioma; neck; treatment; adult patient

## AUTHOR AFFILIATIONS

<sup>1</sup> Medical School, National and Kapodistrian University of Athens, Greece

<sup>2</sup> ENT Department, General Hospital of Tripoli "Evangelistria", Greece

<sup>3</sup> Department of Oral and Maxillofacial Surgery, General Hospital of Tripolis "Evangelistria" Greece

\* Corresponding author: Department of Oral and Maxillofacial Surgery, General Hospital of Tripolis "Evangelistria", Greece;  
email: tzortzisgnatho@gmail.com

Received: 13 July 2021

Accepted: 23 October 2021

Published online: 4 March 2022

---

Acta Medica (Hradec Králové) 2021; 64(4): 224–226

<https://doi.org/10.14712/18059694.2022.6>

© 2021 The Authors. This is an open-access article distributed under the terms of the Creative Commons Attribution License (<http://creativecommons.org/licenses/by/4.0>), which permits unrestricted use, distribution, and reproduction in any medium, provided the original author and source are credited.

## INTRODUCTION

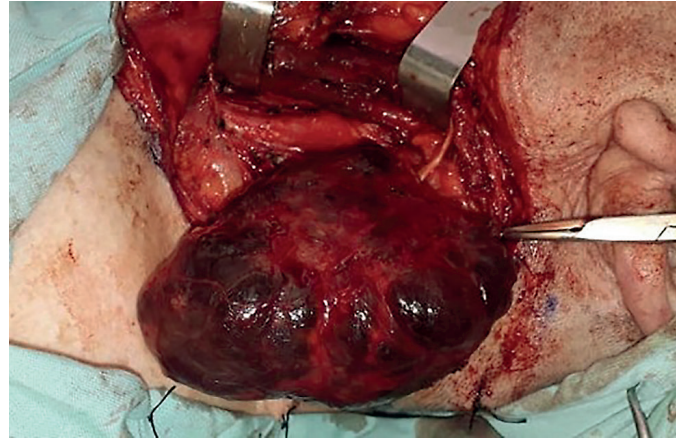
Lymphangioma of the neck is an uncommon benign tumour arising from the cervical lymphatic vessels. Almost 90% of these lesions are diagnosed before the age of two years old and only a few cases of lymphangiomas are reported in adult patients (1). There are three morphological types described: capillary, cavernous and cystic (1). Despite the rarity of this pathology, lymphangioma should be included in the differential diagnosis of cervical masses (2). Diagnosis is based on previous medical history followed by ultrasonography (US) of the neck, magnetic resonance imaging (MRI), contrast-enhanced computed tomography (CECT), while fine needle aspiration cytology (FNAC) may also be used to assist in the diagnosis (1, 3). However, a definitive diagnosis is provided by histological examination (2). Complete surgical resection should be considered as the treatment of choice (3).

In this paper, we present the diagnostic and treatment approach of a cervical cystic lymphangioma (CL) in an adult male.

## CASE PRESENTATION

An 85-year-old male was referred to the outpatient clinic of the Department of Oral and Maxillofacial Surgery with a history of a left-sided neck mass. The mass has been present for the last 15 years, but its size had increased during the last three months. The main complaints were a rapid increase in size and mild hoarseness of voice.

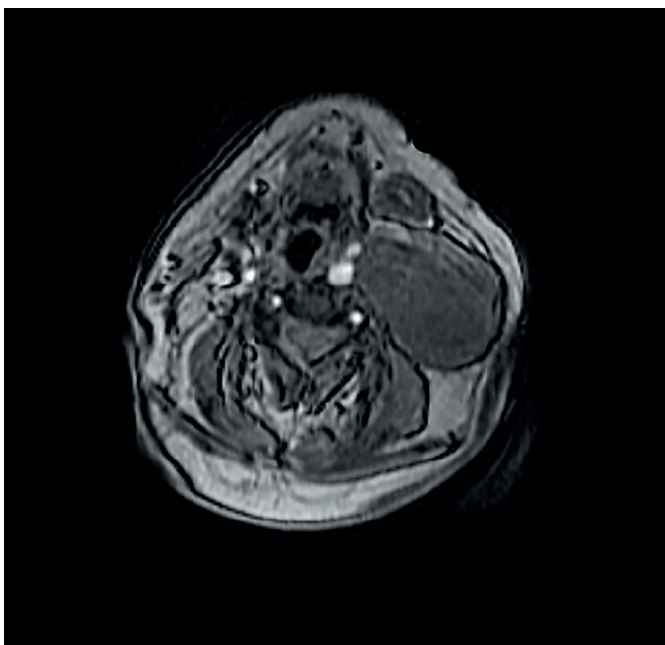
A nontender, soft and mobile mass was palpated in the left side of the neck. The overlying skin was intact. US showed a fluid-filled mass  $9.0 \times 3.5$  cm in size in contact with the left thyroid lobe. FNAC was performed and 48 cc



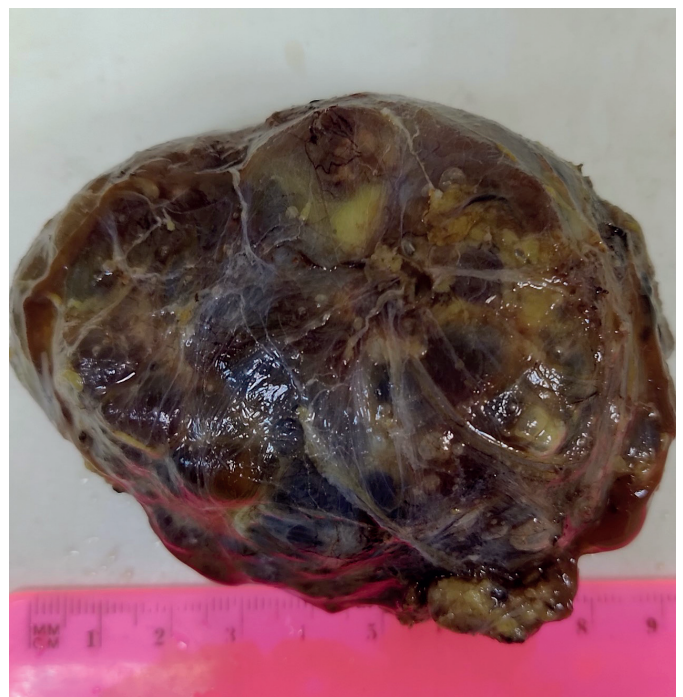
**Fig. 2** Intra-operatively the mass was dark grey in color, and appeared fluid filled and lobulated.

of bloody fluid were aspirated. Cytologic examination revealed a great number of small lymphocytes as well as histiocytes and no malignant cells. CL was suggested as a possible diagnosis. MRI of the neck showed a well-circumscribed lobulated mass,  $9.0 \times 5.4 \times 5.0$  cm in size with fluid-like intensity, located under the sternocleidomastoid muscle. The mass was in contact with the common carotid artery and caused mild deviation of the larynx (Figure 1).

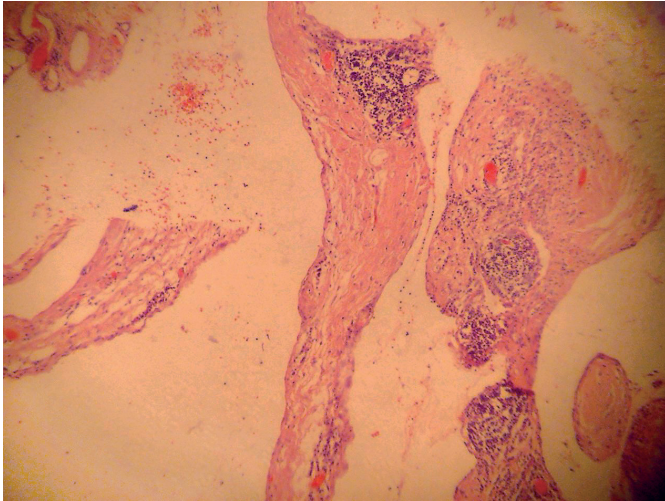
The patient underwent complete surgical excision of the lesion with dissection and preservation of the vital anatomic structures (Figure 2). A soft dark grey cystic mass  $9.0 \times 5.4 \times 5.0$  cm in size was removed in entirety from the left lateral neck (Figure 3). Histological examination confirmed the diagnosis of CL (Figure 4). The post-operative period was uneventful, and the patient was discharged 5 days after the surgery. He remains asymptomatic 1 year later with no signs of recurrence.



**Fig. 1** MRI scan (axial view) of the neck, showing a well-defined mass located in the left side deep to the sternocleidomastoid muscle near to the carotid artery.



**Fig. 3** Macroscopic view of the specimen.



**Fig. 4** Microscopic view of the cyst wall. Vascular spaces are large, irregular and dilated. The stroma consists of fibrous tissue and within it there are lymphoid aggregates.

## DISCUSSION

CL is an extremely rare lymphatic vascular malformation in adults. The most common sites of presentation include the posterior triangle of the neck (75%), axilla (20%), mediastinum (5%), groin, retroperitoneal space and pelvis (4).

Cervical CL may present as a painless, soft and mobile mass of variable size in the neck region (5, 6). Most patients are asymptomatic, although it may rarely cause compression symptoms, such as dysphagia, hoarseness of voice and airway obstruction (3, 5, 7). Mild pain may also be noted (3).

In adult patients, the differential diagnosis includes branchial cleft cysts, dermoid cysts, and lymph node neoplasms (3).

Accurate preoperative evaluation plays an important role in the management of CL. US and MRI scan are the best-used imaging modalities (5). CECT can also be used (3). The role of FNAC is still controversial, since it may be complicated by infection, haemorrhage or recurrence (6). However, FNAC may rule out malignancy (1). Eventually, histological examination provides a definitive diagnosis (3).

Complete surgical removal with preservation of the vital anatomic structures and functionality is the mainstay

of treatment (5). However, in some instances, this might be not possible, since the lesion may surround vital structures (1). In addition, a lack of a capsule can lead to infiltration of the neighbouring structures, making surgical excision harder (7). Incomplete removal of the lesion is associated with higher rates of recurrence (4). Alternative treatment approaches are radiofrequency ablation, CO<sub>2</sub> laser, electrocoagulation, cryotherapy and sclerotherapy (3, 8). These approaches can be used in combination with surgery in larger lesions (3).

The recurrence rate of CL is near 15% (5), whereas partial resection of the lesion can have a recurrence rate as high as 88% (3). Long-term follow-up time may vary depending on the extent of the resection.

## CONCLUSION

Despite its rarity, CL should be included in the differential diagnosis of cervical masses. Diagnosis depends on medical history, US of the neck, MRI, CECT and FNAC. Total surgical excision of the mass is the treatment of choice. In our case, the patient was mainly asymptomatic except for mild hoarseness of voice. FNAC suggested the lymphovascular origin of the lesion and the MRI depicted a well-defined lobulated mass that mildly deviated the trachea. Total excision of the mass was accomplished. He remains asymptomatic 1 year later.

## REFERENCES

1. Kraus J, Plzák J, Bruschini R, et al. Cystic lymphangioma of the neck in adults: a report of three cases. *Wien Klin Wochenschr* 2008; 120: 242-5.
2. Karkos PD, Spencer MG, Lee M, et al. Cervical cystic hygroma/lymphangioma: an acquired idiopathic late presentation. *J Laryngol Otol* 2005; 119: 561-3.
3. Kaira V, Kaira P, Agarawal T. Cervical Cystic Lymphangiomas in Adults: A Case Series of a Rare Entity with Literature Review. *Head Neck Pathol* 2021; 15: 503-8.
4. Mathew M, Dil SK. Adult lymphangioma - a rare entity: a report of two cases. *Turk Patoloji Derg* 2012; 28: 80-2.
5. Aydin S, Demir MG, Selek A. A Giant Lymphangioma on the Neck. *J Craniofac Surg* 2015; 26: e323-5.
6. Colangeli W, Facchini V, Kapitonov A, et al. Cystic lymphangioma in adult: a case report and a review of the literature. *J Surg Case Rep* 2020; 7: rjaa179.
7. Paladino NC, Scerrino G, Chianetta D, et al. Recurrent cystic lymphangioma of the neck. Case report. *Ann Ital Chir* 2014; 85: 69-74.
8. Damaskos C, Garmpis N, Manousi M, et al. Cystic hygroma of the neck: single center experience and literature review. *Eur Rev Med Pharmacol Sci* 2017; 21: 4918-23.